

Visual Inspection of the Cervix

FLASH CARD SET

innovating to save lives



an affiliate of Johns Hopkins University

Jhpiego is an international, non-profit health organization affiliated with The Johns Hopkins University. For nearly 40 years, Jhpiego has empowered front-line health workers by designing and implementing effective, low-cost, hands-on solutions to strengthen the delivery of health care services for women and their families. By putting evidence-based health innovations into everyday practice, Jhpiego works to break down barriers to high-quality health care for the world's most vulnerable populations.

Copyright © 2003 by Jhpiego. All rights reserved. Reprinted 2008.

Published by:
Jhpiego
Brown's Wharf
1615 Thames Street
Baltimore, Maryland 21231-3492, USA
www.jhpiego.org

Author: Paul Blumenthal

Development: Deborah Raynor
Sonia Elabd

Jhpiego gratefully acknowledges the valuable contributions of the following individuals who provided cervical images for the flash cards:

Francisco Garcia — University of Arizona
José Jerónimo — Pan American Health Organization/World Health Organization
R. Sankaranayanan — International Agency for Research on Cancer
Tom Wright — Columbia University

Additional images were provided by Paul Blumenthal.

Jhpiego also wishes to thank Fredrik Broekhuizen for his constructive review of the flash cards.

Funding provided by the Bill & Melinda Gates Foundation through the Alliance for Cervical Cancer Prevention. The opinions expressed herein are those of Jhpiego.

Overview

This set of flash cards was developed to help healthcare providers (doctors, nurses, nurse-midwives, and others) test for cervical precancer and cancer using visual inspection with acetic acid (VIA). These cards can be used in a variety of ways:

- As a training tool together with the reference manual *Cervical Cancer Prevention for Low-Resource Settings* and other learning materials, including the *Cervical Cancer Prevention Course Notebook for Trainers*
- As a means of providing refresher training to verify and evaluate the competency of those currently providing VIA-based services in the field
- As a means of providing one component of a quality assurance program together with VIA-based services; when used in this way, quality assurance officers can select a standardized or pre-assigned group of pictures and present them to providers in the field whenever quality assurance visits are made
- As a means of self-review for providers who wish to assess their own skills

The objectives of this tool are to:

- Assist the user in telling the difference between a normal cervix and an abnormal cervix

- Assist trainers and quality assurance officers in assessing VIA competency and quality of services among VIA providers
- Simulate the decision-making process for healthcare providers who are performing VIA

About This Card Set

This card set contains 115 flash cards, which are numbered to allow the provider or trainer to track which cards were viewed during an exercise.

FLASH CARD, FRONT


The front of each card displays a color version of the cervical image.

FLASH CARD, BACK


The back of the card shows the same cervix in black and white, with lines pointing to the squamocolumnar junction (SCJ) and any lesions.

Questions about the cervix and potential management options are listed, followed by the answers. The questions are identical to those used during VIA clinical training.

In the upper right hand corner, there is a “quick reference” symbol that identifies each image as negative (□), positive (▨), or suspicious for cancer (■).



Example of flash card, front (above) and back (below)



These boxes are primarily for trainers or quality assurance officers who want to choose a specific number of positive, negative, and/or cancerous images for a provider to review (rather than a random set).

QUESTION CARD

The **Question Card** lists all possible questions for a cervical image. Providers conducting an exercise on their own should use this card to avoid seeing the answers until they have completely answered all of the questions.

ANSWER SHEETS

This set also contains 10 blank **Answer Sheets** for the provider to record answers for each set of 10 cards reviewed. Each sheet contains a place to record the card number and the provider's answers in sequence. The cards are laminated, allowing answers to be written in dry-erase marker that can later be wiped clean to reuse. Trainers or providers should use copies of the blank sheets when using other writing instruments (e.g., pens, pencils) and when reviewing more than 10 cards at a time.

INDEX

At the end of each set is an **Index Card** that lists the cards by number and by finding (negative, positive, or suspicious for cancer).

Instructions for Use

FOR VIA PROVIDERS

Providers can use the flash cards to strengthen or refresh VIA skills, such as differentiating normal from abnormal cervixes and making judgments about management. Working alone or in pairs, providers can choose which cards to review in an exercise.

For each card, a series of questions is asked. The questions are based on the decision-making process that a healthcare provider would use if caring for a woman with the cervix shown.

To complete an exercise:

1. Shuffle the flash card deck so that the cards can be selected at random.
2. Choose the number of cards to include in the exercise. If working alone, put the **Question Card** next to the pile of flash cards (with color images showing).

Note: Using small groups of cards, rather than all the cards in one sitting, is recommended to avoid becoming too familiar with the images.

3. Make sure enough blank answer sheets (or pieces of paper) are available to record answers. If using the

laminated sheets from this deck, use only erasable markers to record answers.

4. Look at the image on the front of the first card and answer each question in sequence. Write answers on the answer sheets or paper.

Note: If working alone, use the separate **Question Card** to read the questions. If working in pairs, one provider should look at the front of the flash card (with no answers), while the other provider reads questions from the back and guides the partner through the exercise.

5. After completing all the questions for a card, either place the card aside for later review (after all cards are completed), or look at the back of the card to check the correct answers.
6. Repeat the process for the remaining flash cards that were selected.
7. At the end of the exercise, review answers (if not done after each card) for self-assessment or for a trainer to record as an assessment.

Participants with questions about the self-test should seek out a trainer or check the reference manual *Cervical Cancer Prevention for Low-Resource Settings* for more information.

(Instructions for Use continued on next card)

Instructions for Use (continued)

FOR TRAINERS

Trainers can use the flash cards to assess providers' VIA competency. In some cases, the cards can be used to enhance clinical practice. For example, if there are not enough VIA clients—especially if there are few “positive” findings—the trainer can supplement training with a flash card exercise. Using the quick reference boxes or the index, the trainer can choose specific cards from the deck and include “positives.”

Another option is to conduct a review of random images following the procedure in the **For VIA Providers** section, with the trainer and the provider working as a pair.

In either case, the trainee (provider) should record answers on answer sheets or separate pieces of paper during the exercise.

Note: The flash card set includes all images found on the *Visual Inspection for Cervical Cancer Prevention* interactive CD-ROM. If computer-assisted training is not available, the trainer can use the cards (which contain the same images as the CD-ROM) alone to assess provider competency. In this case, the trainer should use the cards listed on the **Final Exam Card** in the index to test providers, and then score them as described in the Cervical Cancer Prevention Course Notebook for Trainers.

ASSURING PERFORMANCE TO STANDARD

These cards can be used to assess VIA competency in the field as part of a program to assure performance to standard (quality assurance), especially if positive patients are lacking during such visits. In this case, the cards can be used as described in the **For Trainers** section. For example, a set of cards with certain characteristics can be selected to insure that several known positives are included in the set.

If quality assurance visits reveal a deficiency in assessment skills, the flash cards can also be used to provide refresher training in the field. The cards will likely be selected (as opposed to random) to include cards that can bolster or refresh providers' skills.

At the beginning of a round of quality assurance visits across a district or province (for example, if each provider is visited twice a year), it is suggested that a fixed set of cards be shown to all providers. This allows a standardized assessment to be made of all providers since they will have looked at the same cards.

Like trainers, quality assurance officers can also conduct a review of random images following the procedure in the **For VIA Providers** section, with the officer and the provider working as a pair.

In either case, the trainee (provider) should record answers on answer sheets or separate pieces of paper during the exercise.

Significance of Acetowhite Lesions

This graphic provides guidance on how to interpret visual findings with respect to areas that are acetowhite when performing VIA.



Acetowhite area far away from the squamocolumnar junction (SCJ) is not significant



Faint acetowhite areas without sharp outline are not significant



Streak-like acetowhitening is not significant



A line-like acetowhitening appearing at the brim of endocervix is usually not significant



Dot-like pale areas in the endocervix; they are due to grape-like columnar epithelium staining with acetic acid, which is normal



Thick, well-defined acetowhite areas, appearing immediately adjacent to the SCJ, jutting into both endocervix and ectocervix; **they are significant**

Adapted from: International Agency for Research on Cancer (IARC).

The graphic helps providers to tell the difference between areas that appear acetowhite and that may or may not be clinically significant.

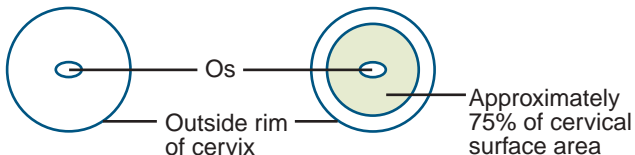
Eligibility for Cryotherapy

Below are the criteria that must be met before the provider can offer cryotherapy to a woman at the time of VIA:

- VIA-positive
- Lesion(s) is not suspicious for cancer
- Lesion(s) occupies less than 75% of the area of the cervix
- Lesion(s) does not extend onto the vaginal wall
- There is no anatomical deformity, such as the cervix being scarred and adherent to the vaginal wall
- Lesion(s) extends less than 2 mm beyond the outer diameter or the inner tip of the cryotherapy probe

If any of the above conditions are **not** met, refer the women to an appropriate facility where additional diagnostic and treatment methods are possible and medical backup is available.

TYPICAL CERVIX



Question Card

- Question 1** Is the cervix suspicious for cancer?
- Question 2** If the squamocolumnar junction (SCJ) can be seen on the cervix, point to it.
- Question 3** Is the cervix VIA-positive or VIA-negative?

If the answer to Question 3 is "VIA-negative," skip Questions 4–5. If the answer is "VIA-positive," answer the questions below.

- Question 4** Point to the acetowhite lesion(s) on the cervix.
- Question 5** Is this patient a good candidate for cryotherapy?

innovating to save lives



an affiliate of Johns Hopkins University

Funding provided by the Bill & Melinda Gates Foundation through the Alliance for Cervical Cancer Prevention. The opinions expressed herein are those of Jhpiego.

Answer Sheet

FLASH CARD NO. _____

Question 1 _____

Question 2 Point to the squamocolumnar junction (SCJ) on the cervix.

If the SCJ is not visible, check here:

Question 3 _____

If the answer to Question 3 is "VIA-negative," skip Questions 4–5. If the answer is "VIA-positive," answer the questions below.

Question 4 Point to the acetowhite lesion(s) on the cervix.

If there are no lesions, check here:

Question 5 _____

innovating to save lives



an affiliate of Johns Hopkins University

Funding provided by the Bill & Melinda Gates Foundation through the Alliance for Cervical Cancer Prevention. The opinions expressed herein are those of Jhpiego.

Answer Sheet

FLASH CARD NO. _____

Question 1 _____

Question 2 Point to the squamocolumnar junction (SCJ) on the cervix.

If the SCJ is not visible, check here:

Question 3 _____

If the answer to Question 3 is "VIA-negative," skip Questions 4–5. If the answer is "VIA-positive," answer the questions below.

Question 4 Point to the acetowhite lesion(s) on the cervix.

If there are no lesions, check here:

Question 5 _____

innovating to save lives



an affiliate of Johns Hopkins University

Funding provided by the Bill & Melinda Gates Foundation through the Alliance for Cervical Cancer Prevention. The opinions expressed herein are those of Jhpiego.

Answer Sheet

FLASH CARD NO. _____

Question 1 _____

Question 2 Point to the squamocolumnar junction (SCJ) on the cervix.

If the SCJ is not visible, check here:

Question 3 _____

If the answer to Question 3 is "VIA-negative," skip Questions 4–5. If the answer is "VIA-positive," answer the questions below.

Question 4 Point to the acetowhite lesion(s) on the cervix.

If there are no lesions, check here:

Question 5 _____

innovating to save lives



an affiliate of Johns Hopkins University

Funding provided by the Bill & Melinda Gates Foundation through the Alliance for Cervical Cancer Prevention. The opinions expressed herein are those of Jhpiego.

Answer Sheet

FLASH CARD NO. _____

Question 1 _____

Question 2 Point to the squamocolumnar junction (SCJ) on the cervix.

If the SCJ is not visible, check here:

Question 3 _____

If the answer to Question 3 is "VIA-negative," skip Questions 4–5. If the answer is "VIA-positive," answer the questions below.

Question 4 Point to the acetowhite lesion(s) on the cervix.

If there are no lesions, check here:

Question 5 _____

innovating to save lives



an affiliate of Johns Hopkins University

Funding provided by the Bill & Melinda Gates Foundation through the Alliance for Cervical Cancer Prevention. The opinions expressed herein are those of Jhpiego.

Answer Sheet

FLASH CARD NO. _____

Question 1 _____

Question 2 Point to the squamocolumnar junction (SCJ) on the cervix.

If the SCJ is not visible, check here:

Question 3 _____

If the answer to Question 3 is "VIA-negative," skip Questions 4–5. If the answer is "VIA-positive," answer the questions below.

Question 4 Point to the acetowhite lesion(s) on the cervix.

If there are no lesions, check here:

Question 5 _____

innovating to save lives



an affiliate of Johns Hopkins University

Funding provided by the Bill & Melinda Gates Foundation through the Alliance for Cervical Cancer Prevention. The opinions expressed herein are those of Jhpiego.

Answer Sheet

FLASH CARD NO. _____

Question 1 _____

Question 2 Point to the squamocolumnar junction (SCJ) on the cervix.

If the SCJ is not visible, check here:

Question 3 _____

If the answer to Question 3 is "VIA-negative," skip Questions 4–5. If the answer is "VIA-positive," answer the questions below.

Question 4 Point to the acetowhite lesion(s) on the cervix.

If there are no lesions, check here:

Question 5 _____

innovating to save lives



an affiliate of Johns Hopkins University

Funding provided by the Bill & Melinda Gates Foundation through the Alliance for Cervical Cancer Prevention. The opinions expressed herein are those of Jhpiego.

Answer Sheet

FLASH CARD NO. _____

Question 1 _____

Question 2 Point to the squamocolumnar junction (SCJ) on the cervix.

If the SCJ is not visible, check here:

Question 3 _____

If the answer to Question 3 is "VIA-negative," skip Questions 4–5. If the answer is "VIA-positive," answer the questions below.

Question 4 Point to the acetowhite lesion(s) on the cervix.

If there are no lesions, check here:

Question 5 _____

innovating to save lives



an affiliate of Johns Hopkins University

Funding provided by the Bill & Melinda Gates Foundation through the Alliance for Cervical Cancer Prevention. The opinions expressed herein are those of Jhpiego.

Answer Sheet

FLASH CARD NO. _____

Question 1 _____

Question 2 Point to the squamocolumnar junction (SCJ) on the cervix.

If the SCJ is not visible, check here:

Question 3 _____

If the answer to Question 3 is "VIA-negative," skip Questions 4–5. If the answer is "VIA-positive," answer the questions below.

Question 4 Point to the acetowhite lesion(s) on the cervix.

If there are no lesions, check here:

Question 5 _____

innovating to save lives



an affiliate of Johns Hopkins University

Funding provided by the Bill & Melinda Gates Foundation through the Alliance for Cervical Cancer Prevention. The opinions expressed herein are those of Jhpiego.

Answer Sheet

FLASH CARD NO. _____

Question 1 _____

Question 2 Point to the squamocolumnar junction (SCJ) on the cervix.

If the SCJ is not visible, check here:

Question 3 _____

If the answer to Question 3 is "VIA-negative," skip Questions 4–5. If the answer is "VIA-positive," answer the questions below.

Question 4 Point to the acetowhite lesion(s) on the cervix.

If there are no lesions, check here:

Question 5 _____

innovating to save lives



an affiliate of Johns Hopkins University

Funding provided by the Bill & Melinda Gates Foundation through the Alliance for Cervical Cancer Prevention. The opinions expressed herein are those of Jhpiego.

Answer Sheet

FLASH CARD NO. _____

Question 1 _____

Question 2 Point to the squamocolumnar junction (SCJ) on the cervix.

If the SCJ is not visible, check here:

Question 3 _____

If the answer to Question 3 is "VIA-negative," skip Questions 4–5. If the answer is "VIA-positive," answer the questions below.

Question 4 Point to the acetowhite lesion(s) on the cervix.

If there are no lesions, check here:

Question 5 _____

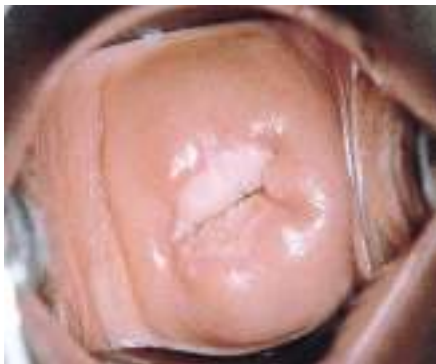innovating to save lives



an affiliate of Johns Hopkins University

Funding provided by the Bill & Melinda Gates Foundation through the Alliance for Cervical Cancer Prevention. The opinions expressed herein are those of Jhpiego.

Flash Card No. 1



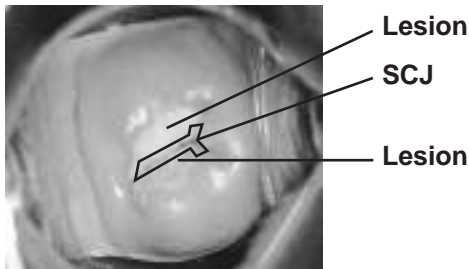
innovating to save lives



an affiliate of Johns Hopkins University



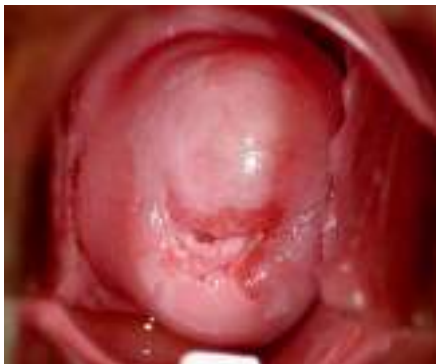Flash Card No. 1 Answers



- Question 1** Is the cervix suspicious for cancer?
No.
- Question 2** If the squamocolumnar junction (SCJ) can be seen on the cervix, point to it.
The SCJ is identified above.
- Question 3** Is the cervix VIA-positive or VIA-negative?
VIA-positive.
- Question 4** Point to the acetowhite lesion(s) on the cervix.
The lesions are identified above.
- Question 5** Is this patient a good candidate for cryotherapy?
Yes.

Funding provided by the Bill & Melinda Gates Foundation through the Alliance for Cervical Cancer Prevention. The opinions expressed herein are those of Jhpiego.

Flash Card No. 2



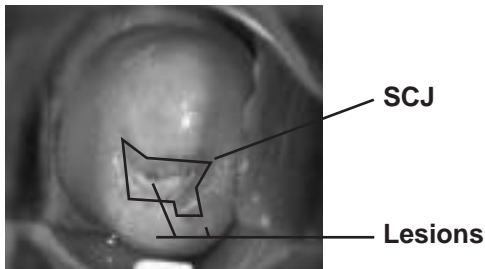
innovating to save lives



an affiliate of Johns Hopkins University



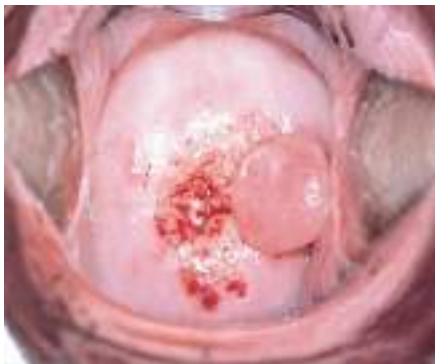Flash Card No. 2 Answers



- Question 1** Is the cervix suspicious for cancer?
No.
- Question 2** If the squamocolumnar junction (SCJ) can be seen on the cervix, point to it.
The SCJ is identified above.
- Question 3** Is the cervix VIA-positive or VIA-negative?
VIA-positive.
- Question 4** Point to the acetowhite lesion(s) on the cervix.
The lesions are identified above.
- Question 5** Is this patient a good candidate for cryotherapy?
No. The lesions extend too far on the cervix (will not be covered by cryoprobe).

Funding provided by the Bill & Melinda Gates Foundation through the Alliance for Cervical Cancer Prevention. The opinions expressed herein are those of Jhpiego.

Flash Card No. 3

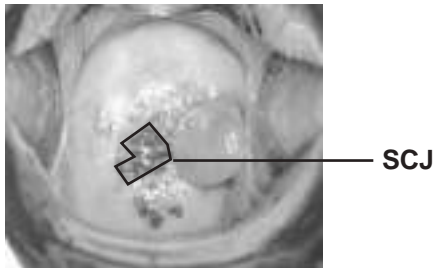


innovating to save lives



an affiliate of Johns Hopkins University

Flash Card No. 3 Answers



Question 1 Is the cervix suspicious for cancer?
No.

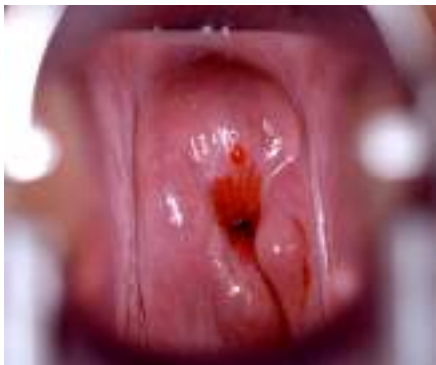Question 2 If the squamocolumnar junction (SCJ) can be seen on the cervix, point to it.
The SCJ is identified above.

Question 3 Is the cervix VIA-positive or VIA-negative?
VIA-negative.

[Answer to Q3 is “VIA-negative,” so Q4–5 are skipped.]

Funding provided by the Bill & Melinda Gates Foundation through the Alliance for Cervical Cancer Prevention. The opinions expressed herein are those of Jhpiego.

Flash Card No. 4

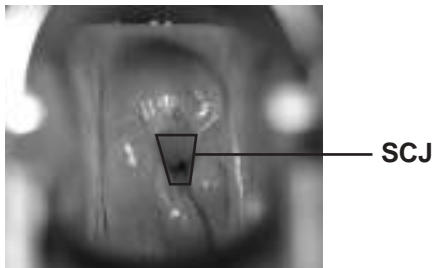


innovating to save lives



an affiliate of Johns Hopkins University

Flash Card No. 4 Answers

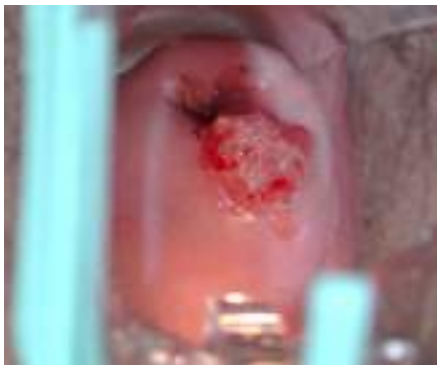

- Question 1** Is the cervix suspicious for cancer?
No.
- Question 2** If the squamocolumnar junction (SCJ) can be seen on the cervix, point to it.
The SCJ is identified above.
- Question 3** Is the cervix VIA-positive or VIA-negative?
VIA-negative.

[Answer to Q3 is “VIA-negative,” so Q4–5 are skipped.]

Funding provided by the Bill & Melinda Gates Foundation through the Alliance for Cervical Cancer Prevention. The opinions expressed herein are those of Jhpiego.

Flash Card No. 5

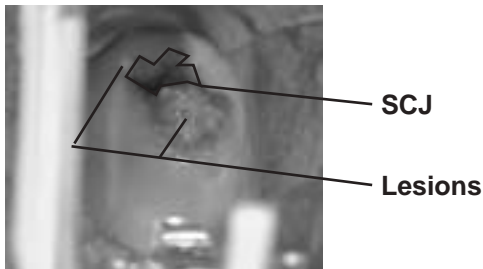


innovating to save lives



an affiliate of Johns Hopkins University

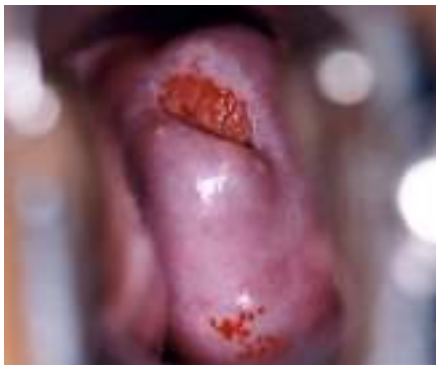Flash Card No. 5 Answers



- Question 1** Is the cervix suspicious for cancer?
Yes.
- Question 2** If the squamocolumnar junction (SCJ) can be seen on the cervix, point to it.
The SCJ is identified above.
- Question 3** Is the cervix VIA-positive or VIA-negative?
VIA-positive.
- Question 4** Point to the acetowhite lesion(s) on the cervix.
The lesions are identified above.
- Question 5** Is this patient a good candidate for cryotherapy?
No, because the cervix is suspicious for cancer.

Funding provided by the Bill & Melinda Gates Foundation through the Alliance for Cervical Cancer Prevention. The opinions expressed herein are those of Jhpiego.

Flash Card No. 6

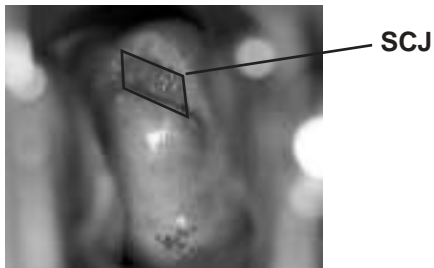


innovating to save lives



an affiliate of Johns Hopkins University

Flash Card No. 6 Answers



Question 1 Is the cervix suspicious for cancer?
No.

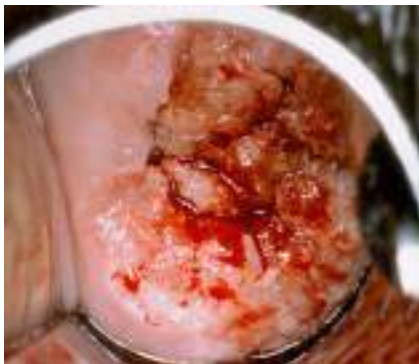
Question 2 If the squamocolumnar junction (SCJ) can be seen on the cervix, point to it.
The SCJ is identified above.

Question 3 Is the cervix VIA-positive or VIA-negative?
VIA-negative.

[Answer to Q3 is “VIA-negative,” so Q4–5 are skipped.]

Funding provided by the Bill & Melinda Gates Foundation through the Alliance for Cervical Cancer Prevention. The opinions expressed herein are those of Jhpiego.

Flash Card No. 7

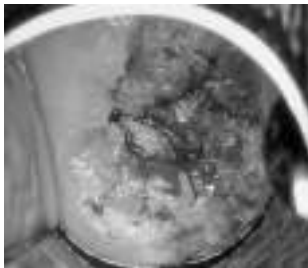


innovating to save lives



an affiliate of Johns Hopkins University

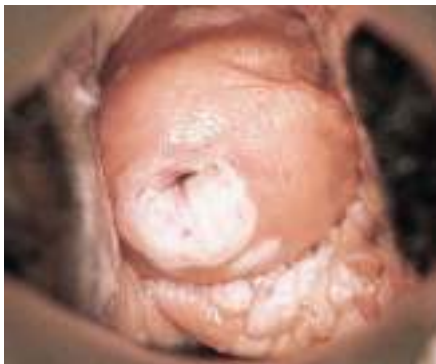Flash Card No. 7 Answers



- Question 1** Is the cervix suspicious for cancer?
Yes.
- Question 2** If the squamocolumnar junction (SCJ) can be seen on the cervix, point to it.
The SCJ is not visible.
- Question 3** Is the cervix VIA-positive or VIA-negative?
VIA-positive.
- Question 4** Point to the acetowhite lesion(s) on the cervix.
The whole cervix is affected.
- Question 5** Is this patient a good candidate for cryotherapy?
No, because the cervix is suspicious for cancer.

Funding provided by the Bill & Melinda Gates Foundation through the Alliance for Cervical Cancer Prevention. The opinions expressed herein are those of Jhpiego.

Flash Card No. 8



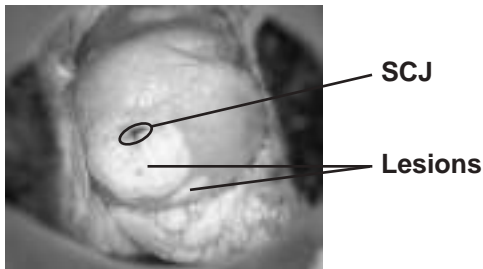
innovating to save lives



an affiliate of Johns Hopkins University



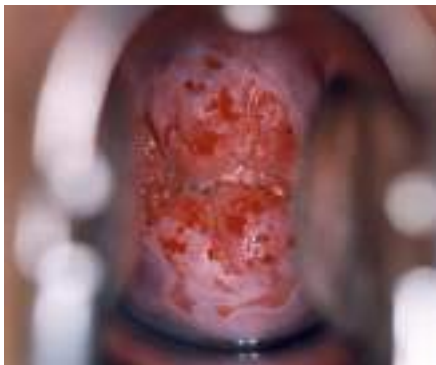Flash Card No. 8 Answers



- Question 1** Is the cervix suspicious for cancer?
No.
- Question 2** If the squamocolumnar junction (SCJ) can be seen on the cervix, point to it.
The SCJ is identified above.
- Question 3** Is the cervix VIA-positive or VIA-negative?
VIA-positive.
- Question 4** Point to the acetowhite lesion(s) on the cervix.
The lesions are identified above.
- Question 5** Is this patient a good candidate for cryotherapy?
Yes. (The provider needs to ensure that the cryoprobe completely covers all lesions.)

Funding provided by the Bill & Melinda Gates Foundation through the Alliance for Cervical Cancer Prevention. The opinions expressed herein are those of Jhpiego.

Flash Card No. 9

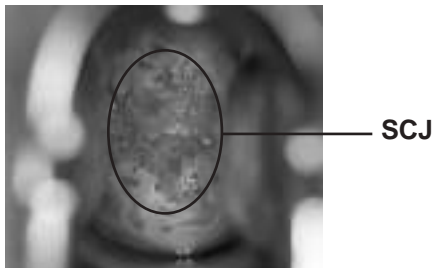


innovating to save lives



an affiliate of Johns Hopkins University

Flash Card No. 9 Answers

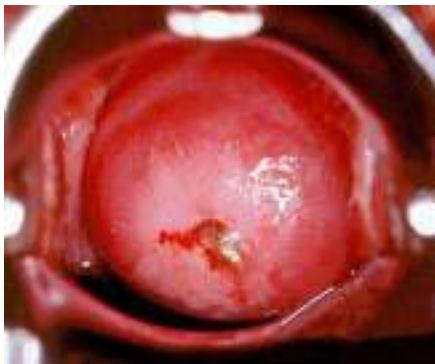

- Question 1** Is the cervix suspicious for cancer?
No.
- Question 2** If the squamocolumnar junction (SCJ) can be seen on the cervix, point to it.
The SCJ is identified above.
- Question 3** Is the cervix VIA-positive or VIA-negative?
VIA-negative.

[Answer to Q3 is “VIA-negative,” so Q4–5 are skipped.]

Funding provided by the Bill & Melinda Gates Foundation through the Alliance for Cervical Cancer Prevention. The opinions expressed herein are those of Jhpiego.

Flash Card No. 10



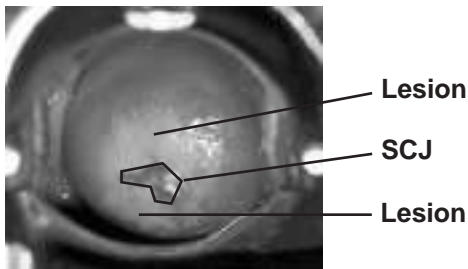
innovating to save lives



an affiliate of Johns Hopkins University



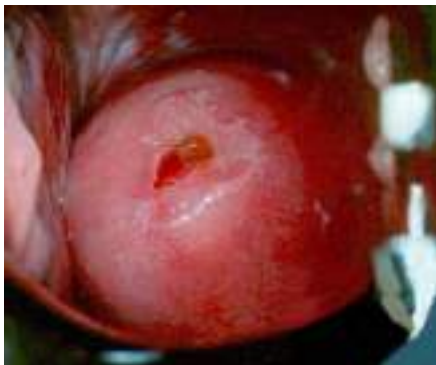Flash Card No. 10 Answers



- Question 1** Is the cervix suspicious for cancer?
No.
- Question 2** If the squamocolumnar junction (SCJ) can be seen on the cervix, point to it.
The SCJ is identified above.
- Question 3** Is the cervix VIA-positive or VIA-negative?
VIA-positive.
- Question 4** Point to the acetowhite lesion(s) on the cervix.
The lesions are identified above.
- Question 5** Is this patient a good candidate for cryotherapy?
No. The lesions extend too far on the cervix (will not be covered by cryoprobe).

Funding provided by the Bill & Melinda Gates Foundation through the Alliance for Cervical Cancer Prevention. The opinions expressed herein are those of Jhpiego.

Flash Card No. 11



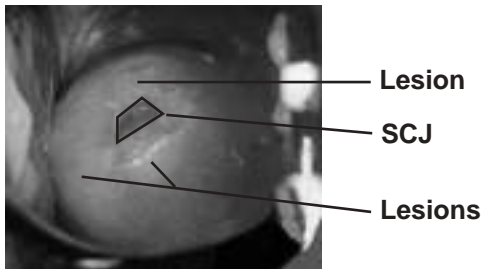
innovating to save lives



an affiliate of Johns Hopkins University



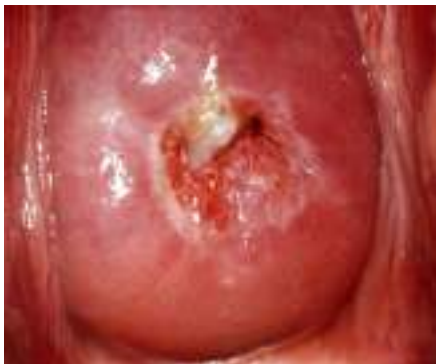Flash Card No. 11 Answers



- Question 1** Is the cervix suspicious for cancer?
No.
- Question 2** If the squamocolumnar junction (SCJ) can be seen on the cervix, point to it.
The SCJ is identified above.
- Question 3** Is the cervix VIA-positive or VIA-negative?
VIA-positive.
- Question 4** Point to the acetowhite lesion(s) on the cervix.
The lesions are identified above.
- Question 5** Is this patient a good candidate for cryotherapy?
No. The lesions extend too far on the cervix (will not be covered by cryoprobe).

Funding provided by the Bill & Melinda Gates Foundation through the Alliance for Cervical Cancer Prevention. The opinions expressed herein are those of Jhpiego.

Flash Card No. 12

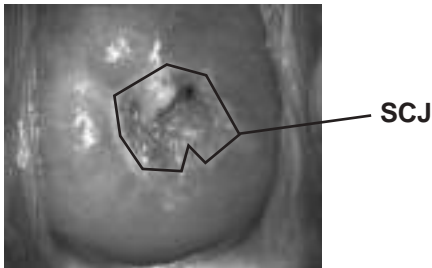


innovating to save lives



an affiliate of Johns Hopkins University

Flash Card No. 12 Answers

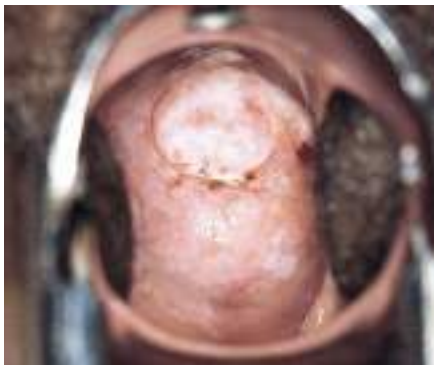

- Question 1** Is the cervix suspicious for cancer?
No.
- Question 2** If the squamocolumnar junction (SCJ) can be seen on the cervix, point to it.
The SCJ is identified above.
- Question 3** Is the cervix VIA-positive or VIA-negative?
VIA-negative.

[Answer to Q3 is “VIA-negative,” so Q4–5 are skipped.]

Funding provided by the Bill & Melinda Gates Foundation through the Alliance for Cervical Cancer Prevention. The opinions expressed herein are those of Jhpiego.

Flash Card No. 13



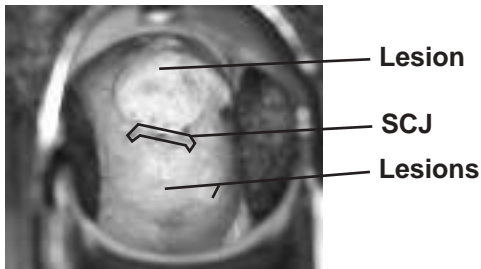
innovating to save lives



an affiliate of Johns Hopkins University



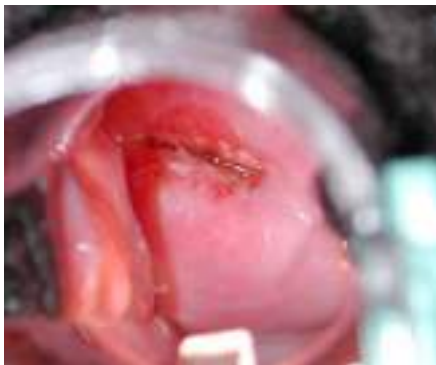Flash Card No. 13 Answers



- Question 1** Is the cervix suspicious for cancer?
No.
- Question 2** If the squamocolumnar junction (SCJ) can be seen on the cervix, point to it.
The SCJ is identified above.
- Question 3** Is the cervix VIA-positive or VIA-negative?
VIA-positive.
- Question 4** Point to the acetowhite lesion(s) on the cervix.
The lesions are identified above.
- Question 5** Is this patient a good candidate for cryotherapy?
No. The lesions extend too far on the cervix (will not be covered by cryoprobe).

Funding provided by the Bill & Melinda Gates Foundation through the Alliance for Cervical Cancer Prevention. The opinions expressed herein are those of Jhpiego.

Flash Card No. 14

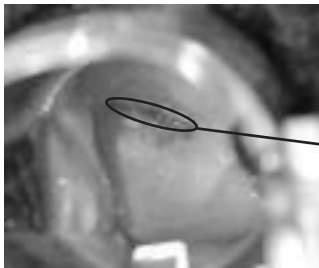


innovating to save lives



an affiliate of Johns Hopkins University

Flash Card No. 14 Answers



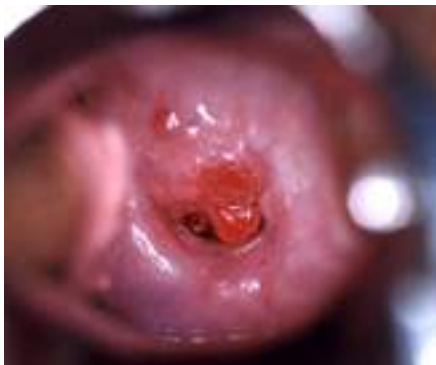SCJ

- Question 1** Is the cervix suspicious for cancer?
No.
- Question 2** If the squamocolumnar junction (SCJ) can be seen on the cervix, point to it.
The SCJ is identified above.
- Question 3** Is the cervix VIA-positive or VIA-negative?
VIA-negative.

[Answer to Q3 is “VIA-negative,” so Q4–5 are skipped.]

Funding provided by the Bill & Melinda Gates Foundation through the Alliance for Cervical Cancer Prevention. The opinions expressed herein are those of Jhpiego.

Flash Card No. 15

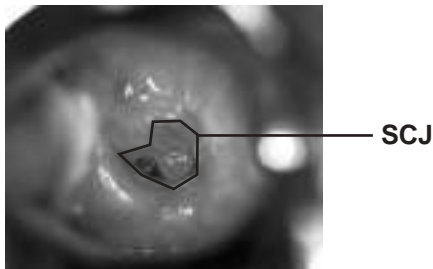


innovating to save lives



an affiliate of Johns Hopkins University

Flash Card No. 15 Answers

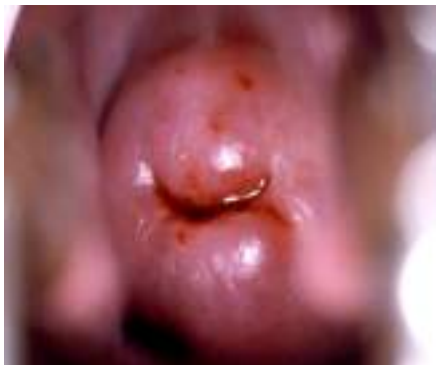

- Question 1** Is the cervix suspicious for cancer?
No.
- Question 2** If the squamocolumnar junction (SCJ) can be seen on the cervix, point to it.
The SCJ is identified above.
- Question 3** Is the cervix VIA-positive or VIA-negative?
VIA-negative.

[Answer to Q3 is “VIA-negative,” so Q4–5 are skipped.]

Funding provided by the Bill & Melinda Gates Foundation through the Alliance for Cervical Cancer Prevention. The opinions expressed herein are those of Jhpiego.

Flash Card No. 16

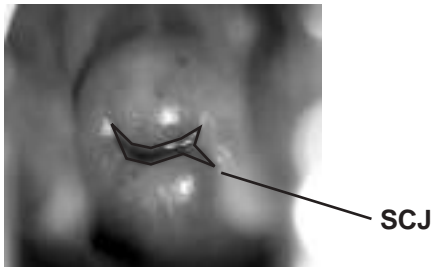


innovating to save lives



an affiliate of Johns Hopkins University

Flash Card No. 16 Answers

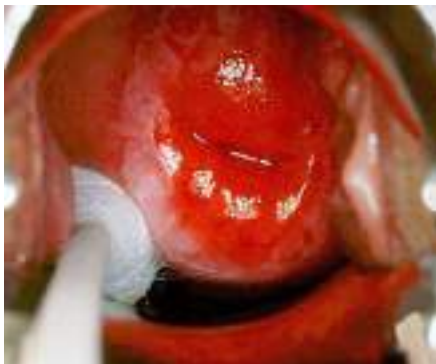

- Question 1** Is the cervix suspicious for cancer?
No.
- Question 2** If the squamocolumnar junction (SCJ) can be seen on the cervix, point to it.
The SCJ is identified above.
- Question 3** Is the cervix VIA-positive or VIA-negative?
VIA-negative.

[Answer to Q3 is “VIA-negative,” so Q4–5 are skipped.]

Funding provided by the Bill & Melinda Gates Foundation through the Alliance for Cervical Cancer Prevention. The opinions expressed herein are those of Jhpiego.

Flash Card No. 17




innovating to save lives



an affiliate of Johns Hopkins University



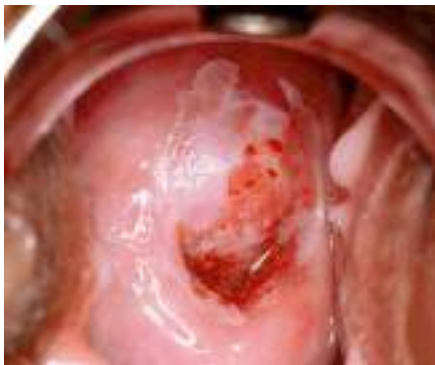Flash Card No. 17 Answers



- Question 1** Is the cervix suspicious for cancer?
No.
- Question 2** If the squamocolumnar junction (SCJ) can be seen on the cervix, point to it.
The SCJ is identified above.
- Question 3** Is the cervix VIA-positive or VIA-negative?
VIA-positive.
- Question 4** Point to the acetowhite lesion(s) on the cervix.
The lesions are identified above.
- Question 5** Is this patient a good candidate for cryotherapy?
Yes.

Funding provided by the Bill & Melinda Gates Foundation through the Alliance for Cervical Cancer Prevention. The opinions expressed herein are those of Jhpiego.

Flash Card No. 18



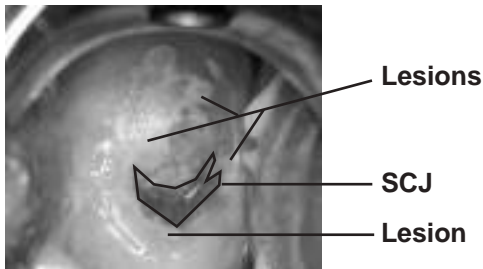
innovating to save lives



an affiliate of Johns Hopkins University



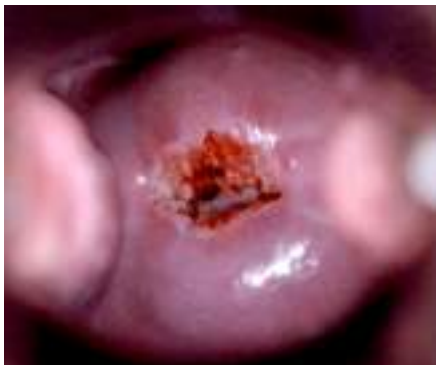Flash Card No. 18 Answers



- Question 1** Is the cervix suspicious for cancer?
No.
- Question 2** If the squamocolumnar junction (SCJ) can be seen on the cervix, point to it.
The SCJ is identified above.
- Question 3** Is the cervix VIA-positive or VIA-negative?
VIA-positive.
- Question 4** Point to the acetowhite lesion(s) on the cervix.
The lesions are identified above.
- Question 5** Is this patient a good candidate for cryotherapy?
Yes.

Funding provided by the Bill & Melinda Gates Foundation through the Alliance for Cervical Cancer Prevention. The opinions expressed herein are those of Jhpiego.

Flash Card No. 19

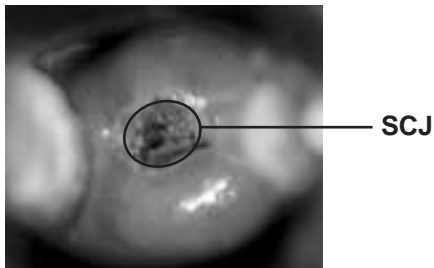


innovating to save lives



an affiliate of Johns Hopkins University

Flash Card No. 19 Answers

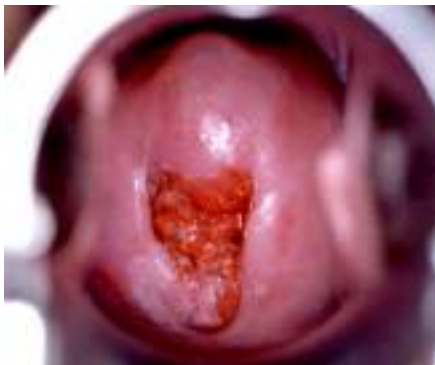

- Question 1** Is the cervix suspicious for cancer?
No.
- Question 2** If the squamocolumnar junction (SCJ) can be seen on the cervix, point to it.
The SCJ is identified above.
- Question 3** Is the cervix VIA-positive or VIA-negative?
VIA-negative.

[Answer to Q3 is “VIA-negative,” so Q4–5 are skipped.]

Funding provided by the Bill & Melinda Gates Foundation through the Alliance for Cervical Cancer Prevention. The opinions expressed herein are those of Jhpiego.

Flash Card No. 20



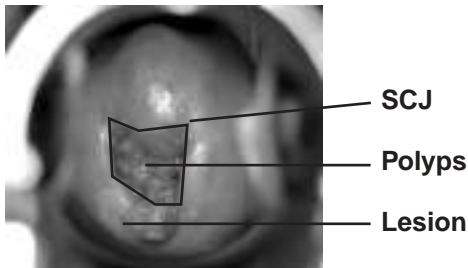
innovating to save lives



an affiliate of Johns Hopkins University



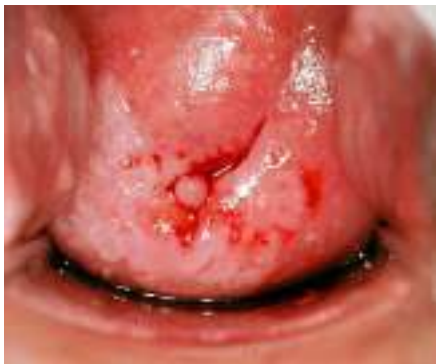Flash Card No. 20 Answers



- Question 1** Is the cervix suspicious for cancer?
No.
- Question 2** If the squamocolumnar junction (SCJ) can be seen on the cervix, point to it.
The SCJ is identified above.
- Question 3** Is the cervix VIA-positive or VIA-negative?
VIA-positive.
- Question 4** Point to the acetowhite lesion(s) on the cervix.
The lesion is identified above.
- Question 5** Is this patient a good candidate for cryotherapy?
Yes.

Funding provided by the Bill & Melinda Gates Foundation through the Alliance for Cervical Cancer Prevention. The opinions expressed herein are those of Jhpiego.

Flash Card No. 21



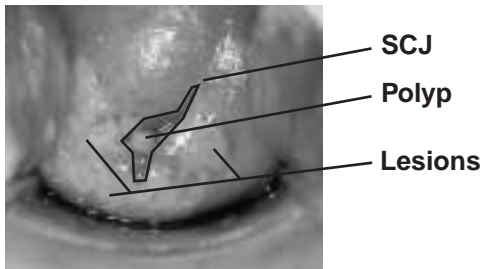
innovating to save lives



an affiliate of Johns Hopkins University



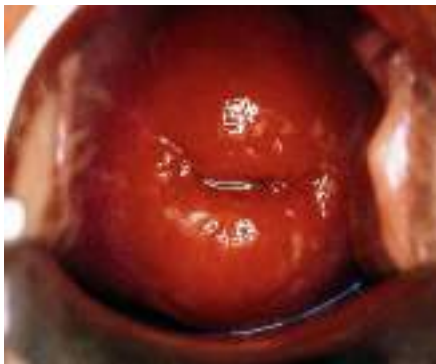Flash Card No. 21 Answers



- Question 1** Is the cervix suspicious for cancer?
No.
- Question 2** If the squamocolumnar junction (SCJ) can be seen on the cervix, point to it.
The SCJ is identified above.
- Question 3** Is the cervix VIA-positive or VIA-negative?
VIA-positive.
- Question 4** Point to the acetowhite lesion(s) on the cervix.
The lesions are identified above.
- Question 5** Is this patient a good candidate for cryotherapy?
No. The lesions extend too far on the cervix (will not be covered by cryoprobe).

Funding provided by the Bill & Melinda Gates Foundation through the Alliance for Cervical Cancer Prevention. The opinions expressed herein are those of Jhpiego.

Flash Card No. 22

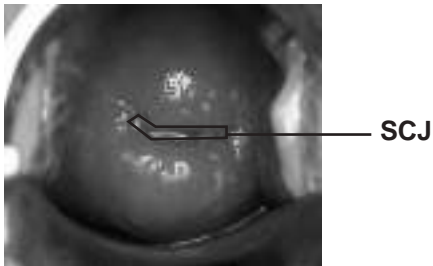


innovating to save lives



an affiliate of Johns Hopkins University

Flash Card No. 22 Answers



Question 1 Is the cervix suspicious for cancer?
No.

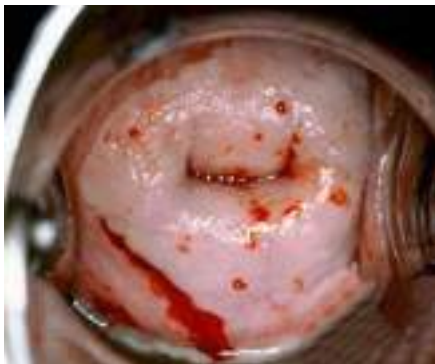Question 2 If the squamocolumnar junction (SCJ) can be seen on the cervix, point to it.
The SCJ is identified above.

Question 3 Is the cervix VIA-positive or VIA-negative?
VIA-negative.

[Answer to Q3 is “VIA-negative,” so Q4–5 are skipped.]

Funding provided by the Bill & Melinda Gates Foundation through the Alliance for Cervical Cancer Prevention. The opinions expressed herein are those of Jhpiego.

Flash Card No. 23



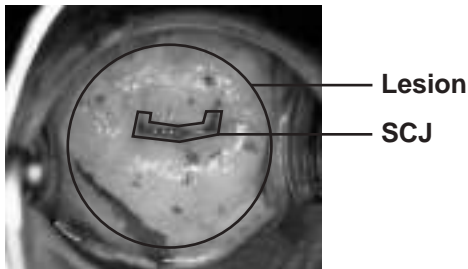
innovating to save lives



an affiliate of Johns Hopkins University



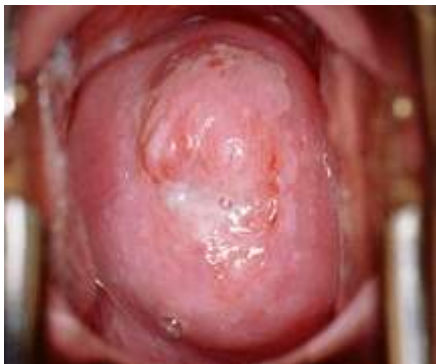Flash Card No. 23 Answers



- Question 1** Is the cervix suspicious for cancer?
No.
- Question 2** If the squamocolumnar junction (SCJ) can be seen on the cervix, point to it.
The SCJ is identified above.
- Question 3** Is the cervix VIA-positive or VIA-negative?
VIA-positive.
- Question 4** Point to the acetowhite lesion(s) on the cervix.
The lesion is identified above.
- Question 5** Is this patient a good candidate for cryotherapy?
No. The lesion extends too far on the cervix (will not be covered by cryoprobe).

Funding provided by the Bill & Melinda Gates Foundation through the Alliance for Cervical Cancer Prevention. The opinions expressed herein are those of Jhpiego.

Flash Card No. 24



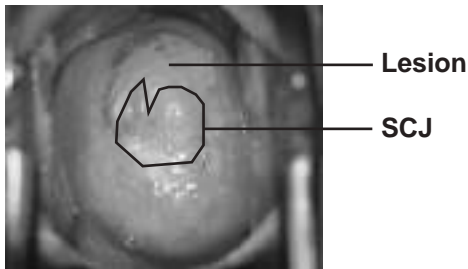
innovating to save lives



an affiliate of Johns Hopkins University



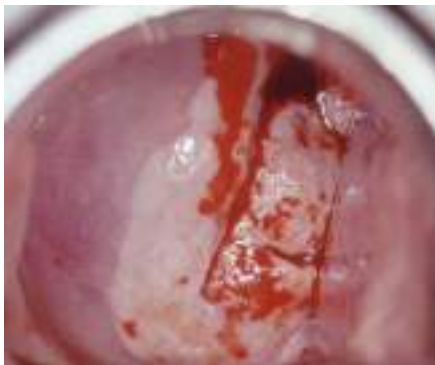Flash Card No. 24 Answers



- Question 1** Is the cervix suspicious for cancer?
No.
- Question 2** If the squamocolumnar junction (SCJ) can be seen on the cervix, point to it.
The SCJ is identified above.
- Question 3** Is the cervix VIA-positive or VIA-negative?
VIA-positive.
- Question 4** Point to the acetowhite lesion(s) on the cervix.
The lesion is identified above.
- Question 5** Is this patient a good candidate for cryotherapy?
No. The lesion extends too far on the cervix (will not be covered by cryoprobe).

Funding provided by the Bill & Melinda Gates Foundation through the Alliance for Cervical Cancer Prevention. The opinions expressed herein are those of Jhpiego.

Flash Card No. 25

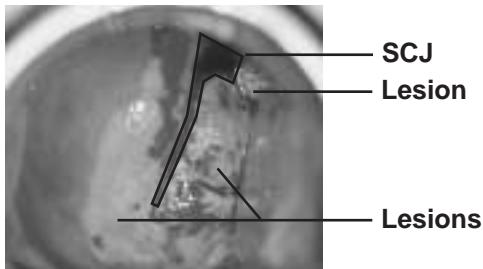


innovating to save lives



an affiliate of Johns Hopkins University

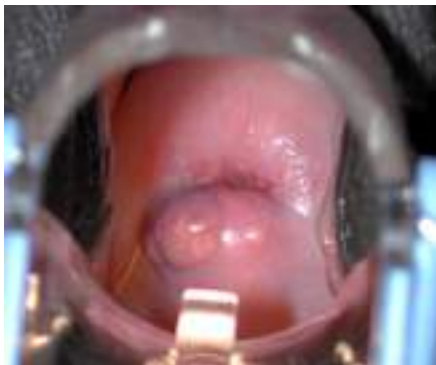Flash Card No. 25 Answers



- Question 1** Is the cervix suspicious for cancer?
Yes.
- Question 2** If the squamocolumnar junction (SCJ) can be seen on the cervix, point to it.
The SCJ is identified above.
- Question 3** Is the cervix VIA-positive or VIA-negative?
VIA-positive.
- Question 4** Point to the acetowhite lesion(s) on the cervix.
The lesions are identified above.
- Question 5** Is this patient a good candidate for cryotherapy?
No, because the cervix is suspicious for cancer.

Funding provided by the Bill & Melinda Gates Foundation through the Alliance for Cervical Cancer Prevention. The opinions expressed herein are those of Jhpiego.

Flash Card No. 26

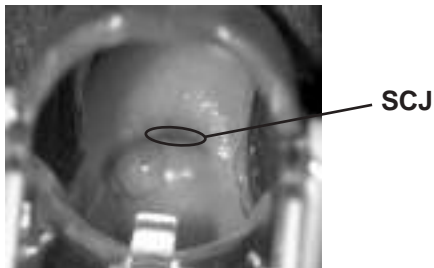


innovating to save lives



an affiliate of Johns Hopkins University

Flash Card No. 26 Answers

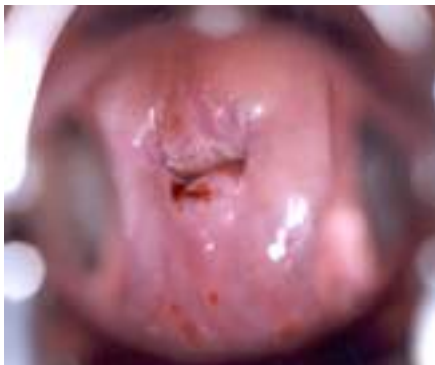

- Question 1** Is the cervix suspicious for cancer?
No.
- Question 2** If the squamocolumnar junction (SCJ) can be seen on the cervix, point to it.
The SCJ is identified above.
- Question 3** Is the cervix VIA-positive or VIA-negative?
VIA-negative.

[Answer to Q3 is “VIA-negative,” so Q4–5 are skipped.]

Funding provided by the Bill & Melinda Gates Foundation through the Alliance for Cervical Cancer Prevention. The opinions expressed herein are those of Jhpiego.

Flash Card No. 27

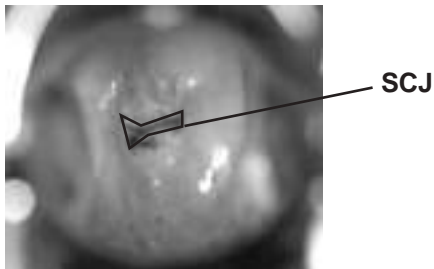


innovating to save lives



an affiliate of Johns Hopkins University

Flash Card No. 27 Answers

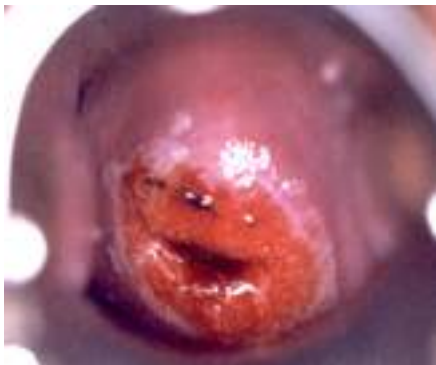

- Question 1** Is the cervix suspicious for cancer?
No.
- Question 2** If the squamocolumnar junction (SCJ) can be seen on the cervix, point to it.
The SCJ is identified above.
- Question 3** Is the cervix VIA-positive or VIA-negative?
VIA-negative.

[Answer to Q3 is “VIA-negative,” so Q4–5 are skipped.]

Funding provided by the Bill & Melinda Gates Foundation through the Alliance for Cervical Cancer Prevention. The opinions expressed herein are those of Jhpiego.

Flash Card No. 28



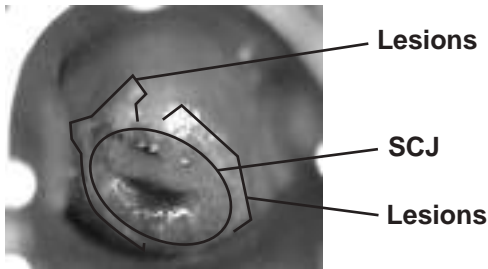
innovating to save lives



an affiliate of Johns Hopkins University



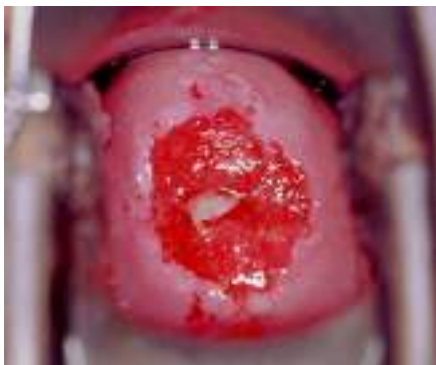Flash Card No. 28 Answers



- Question 1** Is the cervix suspicious for cancer?
No.
- Question 2** If the squamocolumnar junction (SCJ) can be seen on the cervix, point to it.
The SCJ is identified above.
- Question 3** Is the cervix VIA-positive or VIA-negative?
VIA-positive.
- Question 4** Point to the acetowhite lesion(s) on the cervix.
The lesions are identified above.
- Question 5** Is this patient a good candidate for cryotherapy?
Yes.

Funding provided by the Bill & Melinda Gates Foundation through the Alliance for Cervical Cancer Prevention. The opinions expressed herein are those of Jhpiego.

Flash Card No. 29



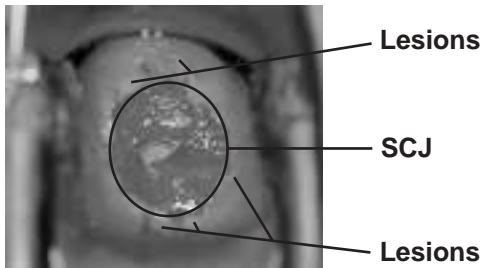
innovating to save lives



an affiliate of Johns Hopkins University



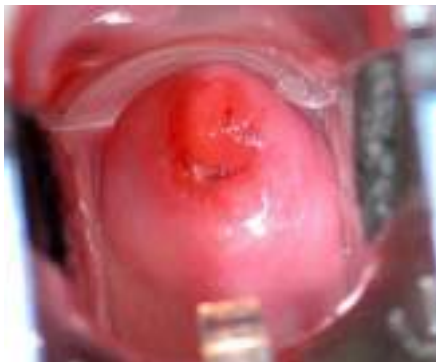Flash Card No. 29 Answers



- Question 1** Is the cervix suspicious for cancer?
No.
- Question 2** If the squamocolumnar junction (SCJ) can be seen on the cervix, point to it.
The SCJ is identified above.
- Question 3** Is the cervix VIA-positive or VIA-negative?
VIA-positive.
- Question 4** Point to the acetowhite lesion(s) on the cervix.
The lesions are identified above.
- Question 5** Is this patient a good candidate for cryotherapy?
Yes.

Funding provided by the Bill & Melinda Gates Foundation through the Alliance for Cervical Cancer Prevention. The opinions expressed herein are those of Jhpiego.

Flash Card No. 30

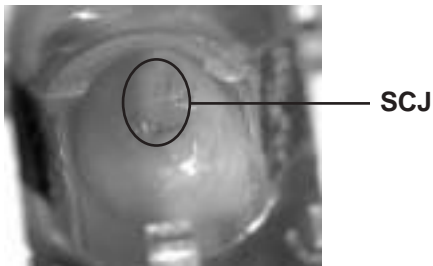


innovating to save lives



an affiliate of Johns Hopkins University

Flash Card No. 30 Answers

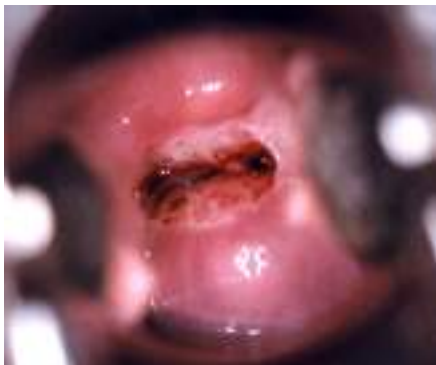

- Question 1** Is the cervix suspicious for cancer?
No.
- Question 2** If the squamocolumnar junction (SCJ) can be seen on the cervix, point to it.
The SCJ is identified above.
- Question 3** Is the cervix VIA-positive or VIA-negative?
VIA-negative.

[Answer to Q3 is “VIA-negative,” so Q4–5 are skipped.]

Funding provided by the Bill & Melinda Gates Foundation through the Alliance for Cervical Cancer Prevention. The opinions expressed herein are those of Jhpiego.

Flash Card No. 31

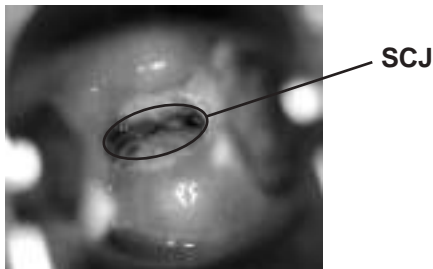


innovating to save lives



an affiliate of Johns Hopkins University

Flash Card No. 31 Answers

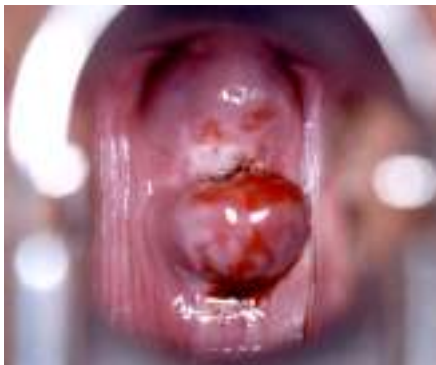

- Question 1** Is the cervix suspicious for cancer?
No.
- Question 2** If the squamocolumnar junction (SCJ) can be seen on the cervix, point to it.
The SCJ is identified above.
- Question 3** Is the cervix VIA-positive or VIA-negative?
VIA-negative.

[Answer to Q3 is “VIA-negative,” so Q4–5 are skipped.]

Funding provided by the Bill & Melinda Gates Foundation through the Alliance for Cervical Cancer Prevention. The opinions expressed herein are those of Jhpiego.

Flash Card No. 32



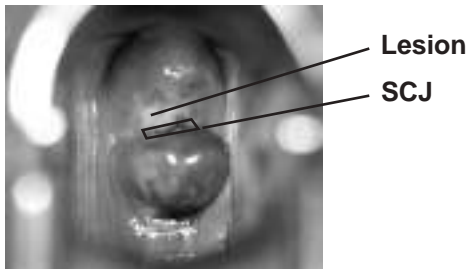
innovating to save lives



an affiliate of Johns Hopkins University



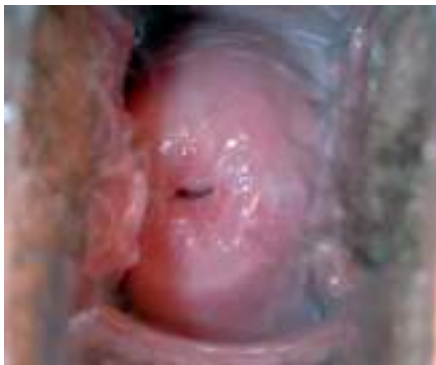Flash Card No. 32 Answers



- Question 1** Is the cervix suspicious for cancer?
No.
- Question 2** If the squamocolumnar junction (SCJ) can be seen on the cervix, point to it.
The SCJ is identified above.
- Question 3** Is the cervix VIA-positive or VIA-negative?
VIA-positive.
- Question 4** Point to the acetowhite lesion(s) on the cervix.
The lesion is identified above.
- Question 5** Is this patient a good candidate for cryotherapy?
Yes.

Funding provided by the Bill & Melinda Gates Foundation through the Alliance for Cervical Cancer Prevention. The opinions expressed herein are those of Jhpiego.

Flash Card No. 33

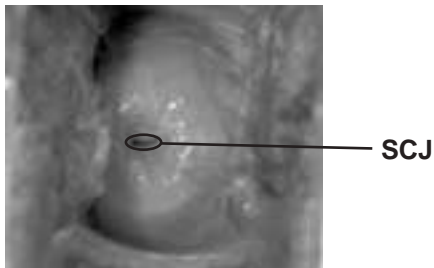


innovating to save lives



an affiliate of Johns Hopkins University

Flash Card No. 33 Answers

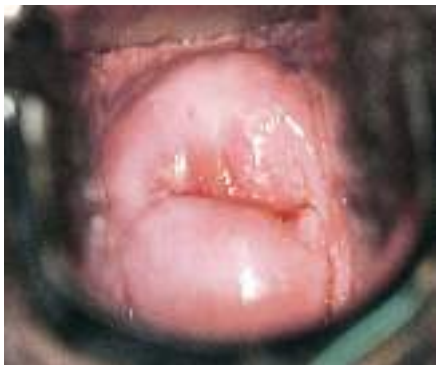

- Question 1** Is the cervix suspicious for cancer?
No.
- Question 2** If the squamocolumnar junction (SCJ) can be seen on the cervix, point to it.
The SCJ is identified above.
- Question 3** Is the cervix VIA-positive or VIA-negative?
VIA-negative.

[Answer to Q3 is “VIA-negative,” so Q4–5 are skipped.]

Funding provided by the Bill & Melinda Gates Foundation through the Alliance for Cervical Cancer Prevention. The opinions expressed herein are those of Jhpiego.

Flash Card No. 34

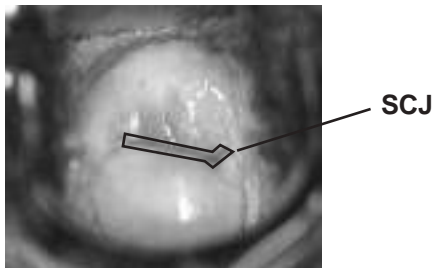


innovating to save lives



an affiliate of Johns Hopkins University

Flash Card No. 34 Answers

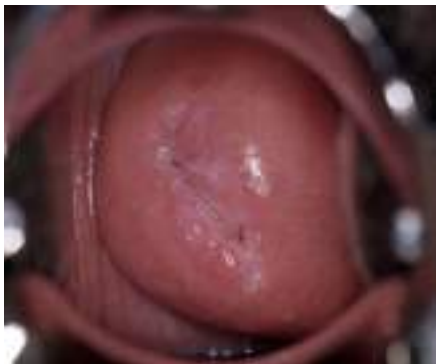

- Question 1** Is the cervix suspicious for cancer?
No.
- Question 2** If the squamocolumnar junction (SCJ) can be seen on the cervix, point to it.
The SCJ is identified above.
- Question 3** Is the cervix VIA-positive or VIA-negative?
VIA-negative.

[Answer to Q3 is “VIA-negative,” so Q4–5 are skipped.]

Funding provided by the Bill & Melinda Gates Foundation through the Alliance for Cervical Cancer Prevention. The opinions expressed herein are those of Jhpiego.

Flash Card No. 35



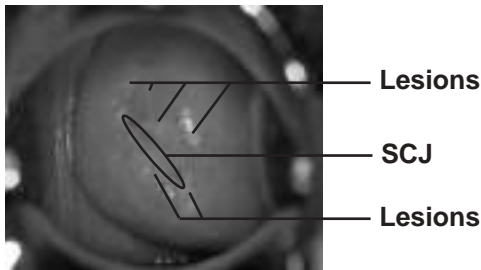
innovating to save lives



an affiliate of Johns Hopkins University



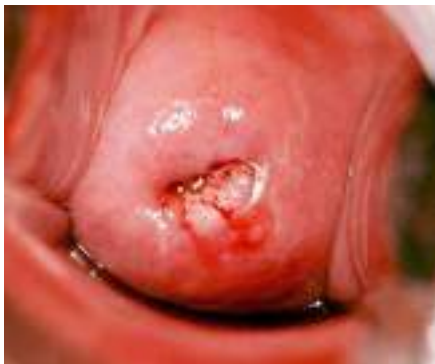Flash Card No. 35 Answers



- Question 1** Is the cervix suspicious for cancer?
No.
- Question 2** If the squamocolumnar junction (SCJ) can be seen on the cervix, point to it.
The SCJ is identified above.
- Question 3** Is the cervix VIA-positive or VIA-negative?
VIA-positive.
- Question 4** Point to the acetowhite lesion(s) on the cervix.
The lesions are identified above.
- Question 5** Is this patient a good candidate for cryotherapy?
Yes.

Funding provided by the Bill & Melinda Gates Foundation through the Alliance for Cervical Cancer Prevention. The opinions expressed herein are those of Jhpiego.

Flash Card No. 36



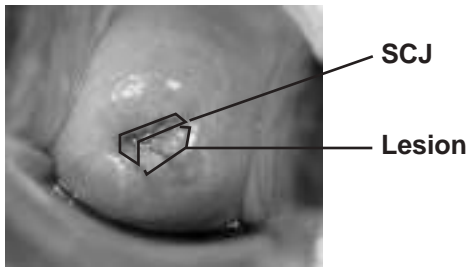
innovating to save lives



an affiliate of Johns Hopkins University



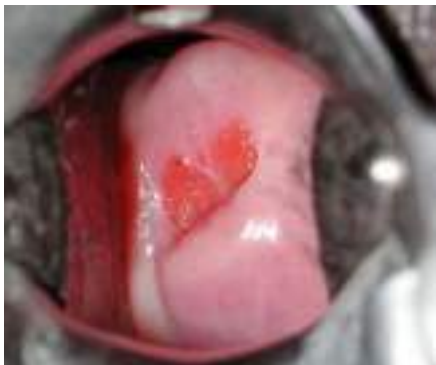Flash Card No. 36 Answers



- Question 1** Is the cervix suspicious for cancer?
No.
- Question 2** If the squamocolumnar junction (SCJ) can be seen on the cervix, point to it.
The SCJ is identified above.
- Question 3** Is the cervix VIA-positive or VIA-negative?
VIA-positive.
- Question 4** Point to the acetowhite lesion(s) on the cervix.
The lesion is identified above.
- Question 5** Is this patient a good candidate for cryotherapy?
Yes.

Funding provided by the Bill & Melinda Gates Foundation through the Alliance for Cervical Cancer Prevention. The opinions expressed herein are those of Jhpiego.

Flash Card No. 37

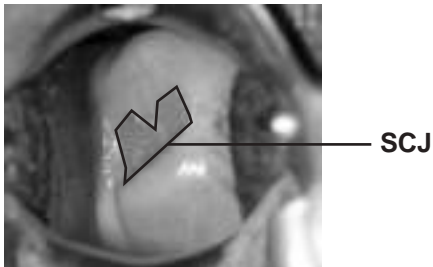


innovating to save lives



an affiliate of Johns Hopkins University

Flash Card No. 37 Answers



Question 1 Is the cervix suspicious for cancer?
No.

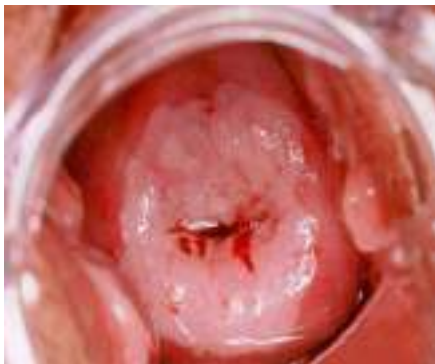Question 2 If the squamocolumnar junction (SCJ) can be seen on the cervix, point to it.
The SCJ is identified above.

Question 3 Is the cervix VIA-positive or VIA-negative?
VIA-negative.

[Answer to Q3 is “VIA-negative,” so Q4–5 are skipped.]

Funding provided by the Bill & Melinda Gates Foundation through the Alliance for Cervical Cancer Prevention. The opinions expressed herein are those of Jhpiego.

Flash Card No. 38




innovating to save lives



an affiliate of Johns Hopkins University



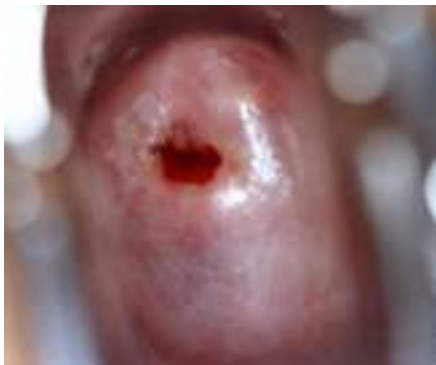Flash Card No. 38 Answers



- Question 1** Is the cervix suspicious for cancer?
No.
- Question 2** If the squamocolumnar junction (SCJ) can be seen on the cervix, point to it.
The SCJ is identified above.
- Question 3** Is the cervix VIA-positive or VIA-negative?
VIA-positive.
- Question 4** Point to the acetowhite lesion(s) on the cervix.
The lesions are identified above.
- Question 5** Is this patient a good candidate for cryotherapy?
No. The lesions extend too far on the cervix (will not be covered by cryoprobe).

Funding provided by the Bill & Melinda Gates Foundation through the Alliance for Cervical Cancer Prevention. The opinions expressed herein are those of Jhpiego.

Flash Card No. 39



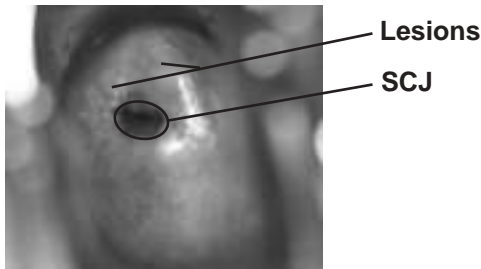
innovating to save lives



an affiliate of Johns Hopkins University



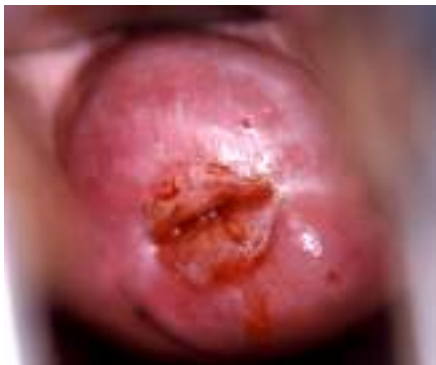Flash Card No. 39 Answers



- Question 1** Is the cervix suspicious for cancer?
No.
- Question 2** If the squamocolumnar junction (SCJ) can be seen on the cervix, point to it.
The SCJ is identified above.
- Question 3** Is the cervix VIA-positive or VIA-negative?
VIA-positive.
- Question 4** Point to the acetowhite lesion(s) on the cervix.
The lesions are identified above.
- Question 5** Is this patient a good candidate for cryotherapy?
Yes.

Funding provided by the Bill & Melinda Gates Foundation through the Alliance for Cervical Cancer Prevention. The opinions expressed herein are those of Jhpiego.

Flash Card No. 40

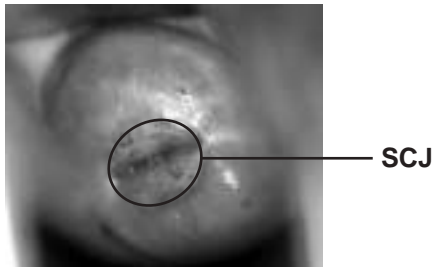


innovating to save lives



an affiliate of Johns Hopkins University

Flash Card No. 40 Answers

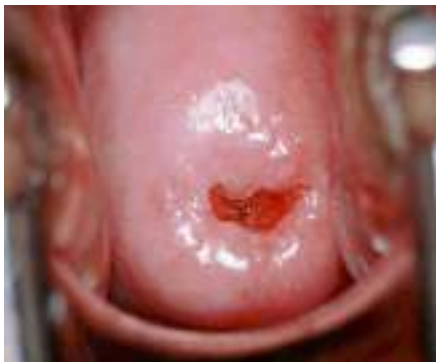

- Question 1** Is the cervix suspicious for cancer?
No.
- Question 2** If the squamocolumnar junction (SCJ) can be seen on the cervix, point to it.
The SCJ is identified above.
- Question 3** Is the cervix VIA-positive or VIA-negative?
VIA-negative.

[Answer to Q3 is “VIA-negative,” so Q4–5 are skipped.]

Funding provided by the Bill & Melinda Gates Foundation through the Alliance for Cervical Cancer Prevention. The opinions expressed herein are those of Jhpiego.

Flash Card No. 41

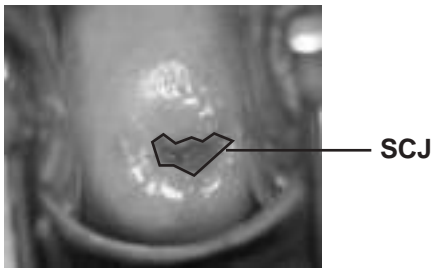


innovating to save lives



an affiliate of Johns Hopkins University

Flash Card No. 41 Answers

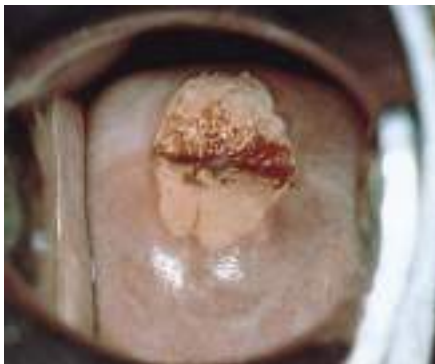


- Question 1** Is the cervix suspicious for cancer?
No.
- Question 2** If the squamocolumnar junction (SCJ) can be seen on the cervix, point to it.
The SCJ is identified above.
- Question 3** Is the cervix VIA-positive or VIA-negative?
VIA-negative.

[Answer to Q3 is “VIA-negative,” so Q4–5 are skipped.]

Funding provided by the Bill & Melinda Gates Foundation through the Alliance for Cervical Cancer Prevention. The opinions expressed herein are those of Jhpiego.

Flash Card No. 42



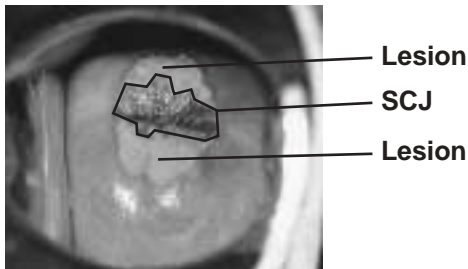
innovating to save lives



an affiliate of Johns Hopkins University



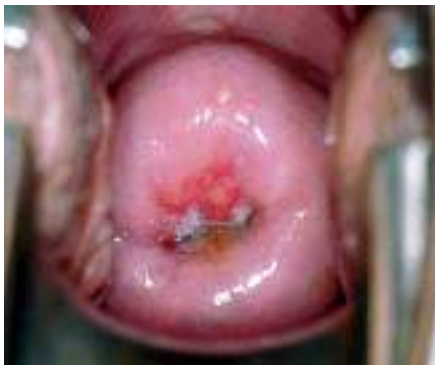Flash Card No. 42 Answers



- Question 1** Is the cervix suspicious for cancer?
No.
- Question 2** If the squamocolumnar junction (SCJ) can be seen on the cervix, point to it.
The SCJ is identified above.
- Question 3** Is the cervix VIA-positive or VIA-negative?
VIA-positive.
- Question 4** Point to the acetowhite lesion(s) on the cervix.
The lesions are identified above.
- Question 5** Is this patient a good candidate for cryotherapy?
Yes.

Funding provided by the Bill & Melinda Gates Foundation through the Alliance for Cervical Cancer Prevention. The opinions expressed herein are those of Jhpiego.

Flash Card No. 43



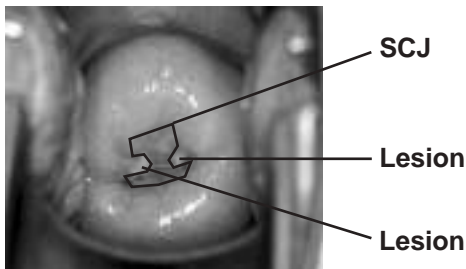
innovating to save lives



an affiliate of Johns Hopkins University



Flash Card No. 43 Answers



Question 1 Is the cervix suspicious for cancer?
No.

Question 2 If the squamocolumnar junction (SCJ) can be seen on the cervix, point to it.
The SCJ is identified above.

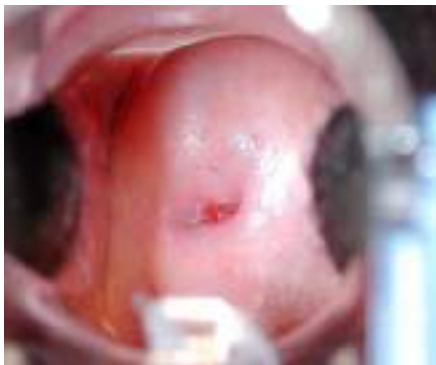Question 3 Is the cervix VIA-positive or VIA-negative?
VIA-positive.

Question 4 Point to the acetowhite lesion(s) on the cervix.
The lesions are identified above.

Question 5 Is this patient a good candidate for cryotherapy?
Yes. (However, because the lesion is close to the endocervix she maybe a good candidate for referral.)

Funding provided by the Bill & Melinda Gates Foundation through the Alliance for Cervical Cancer Prevention. The opinions expressed herein are those of Jhpiego.

Flash Card No. 44

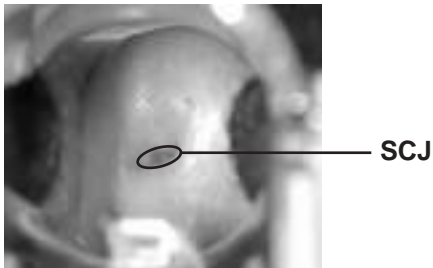


innovating to save lives



an affiliate of Johns Hopkins University

Flash Card No. 44 Answers

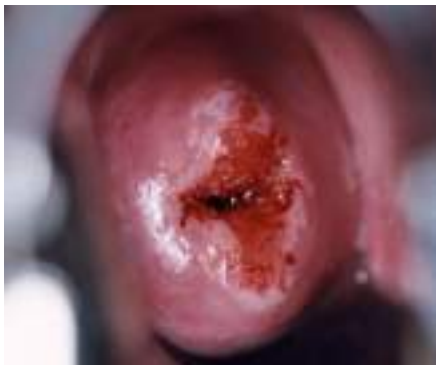

- Question 1** Is the cervix suspicious for cancer?
No.
- Question 2** If the squamocolumnar junction (SCJ) can be seen on the cervix, point to it.
The SCJ is identified above.
- Question 3** Is the cervix VIA-positive or VIA-negative?
VIA-negative.

[Answer to Q3 is “VIA-negative,” so Q4–5 are skipped.]

Funding provided by the Bill & Melinda Gates Foundation through the Alliance for Cervical Cancer Prevention. The opinions expressed herein are those of Jhpiego.

Flash Card No. 45



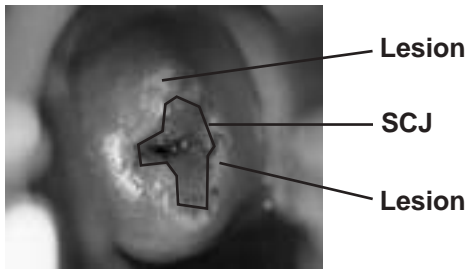
innovating to save lives



an affiliate of Johns Hopkins University



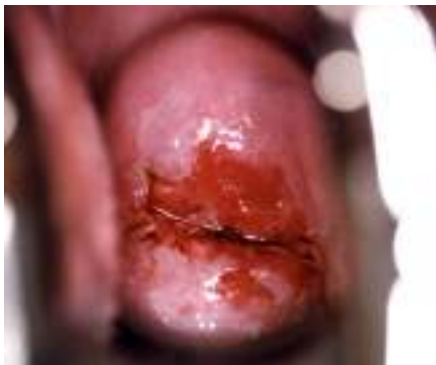Flash Card No. 45 Answers



- Question 1** Is the cervix suspicious for cancer?
No.
- Question 2** If the squamocolumnar junction (SCJ) can be seen on the cervix, point to it.
The SCJ is identified above.
- Question 3** Is the cervix VIA-positive or VIA-negative?
VIA-positive.
- Question 4** Point to the acetowhite lesion(s) on the cervix.
The lesions are identified above.
- Question 5** Is this patient a good candidate for cryotherapy?
Yes.

Funding provided by the Bill & Melinda Gates Foundation through the Alliance for Cervical Cancer Prevention. The opinions expressed herein are those of Jhpiego.

Flash Card No. 46



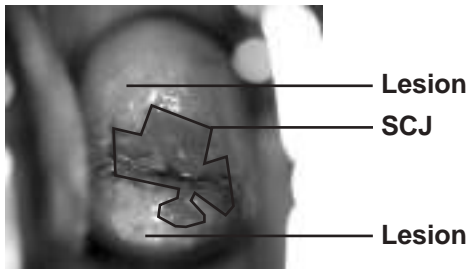
innovating to save lives



an affiliate of Johns Hopkins University



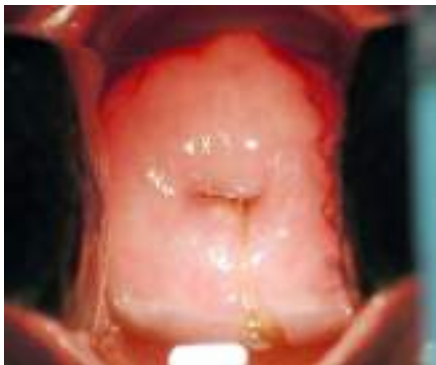
Flash Card No. 46 Answers



- Question 1** Is the cervix suspicious for cancer?
No.
- Question 2** If the squamocolumnar junction (SCJ) can be seen on the cervix, point to it.
The SCJ is identified above.
- Question 3** Is the cervix VIA-positive or VIA-negative?
VIA-positive.
- Question 4** Point to the acetowhite lesion(s) on the cervix.
The lesions are identified above.
- Question 5** Is this patient a good candidate for cryotherapy?
Yes.

Funding provided by the Bill & Melinda Gates Foundation through the Alliance for Cervical Cancer Prevention. The opinions expressed herein are those of Jhpiego.

Flash Card No. 47

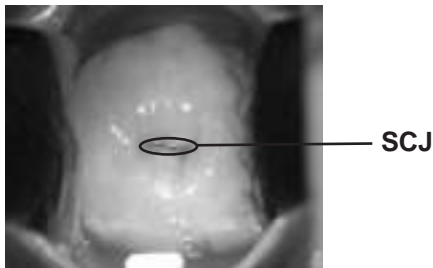


innovating to save lives



an affiliate of Johns Hopkins University

Flash Card No. 47 Answers



Question 1 Is the cervix suspicious for cancer?
No.

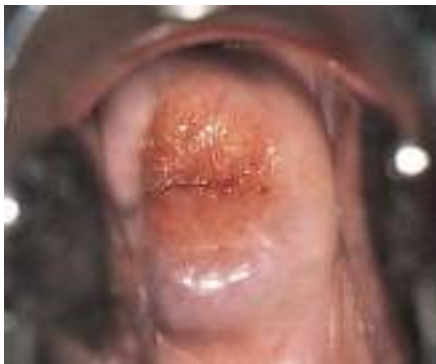Question 2 If the squamocolumnar junction (SCJ) can be seen on the cervix, point to it.
The SCJ is identified above.

Question 3 Is the cervix VIA-positive or VIA-negative?
VIA-negative.

[Answer to Q3 is “VIA-negative,” so Q4–5 are skipped.]

Funding provided by the Bill & Melinda Gates Foundation through the Alliance for Cervical Cancer Prevention. The opinions expressed herein are those of Jhpiego.

Flash Card No. 48

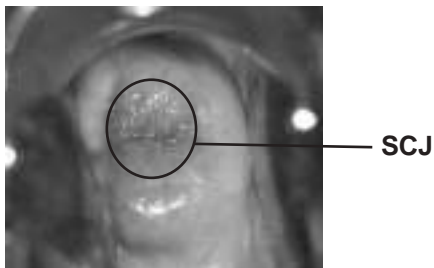


innovating to save lives



an affiliate of Johns Hopkins University

Flash Card No. 48 Answers



Question 1 Is the cervix suspicious for cancer?
No.

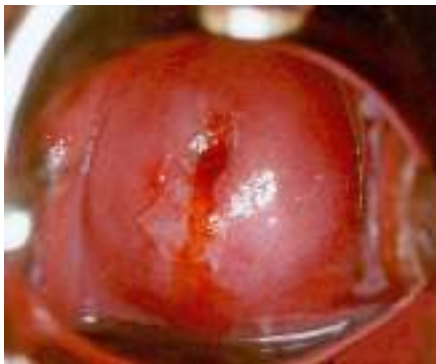Question 2 If the squamocolumnar junction (SCJ) can be seen on the cervix, point to it.
The SCJ is identified above.

Question 3 Is the cervix VIA-positive or VIA-negative?
VIA-negative.

[Answer to Q3 is “VIA-negative,” so Q4–5 are skipped.]

Funding provided by the Bill & Melinda Gates Foundation through the Alliance for Cervical Cancer Prevention. The opinions expressed herein are those of Jhpiego.

Flash Card No. 49



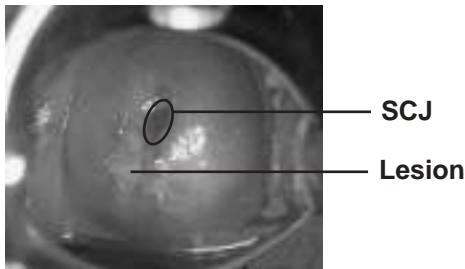
innovating to save lives



an affiliate of Johns Hopkins University



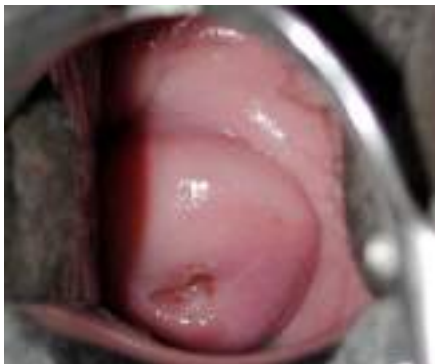Flash Card No. 49 Answers



- Question 1** Is the cervix suspicious for cancer?
No.
- Question 2** If the squamocolumnar junction (SCJ) can be seen on the cervix, point to it.
The SCJ is identified above.
- Question 3** Is the cervix VIA-positive or VIA-negative?
VIA-positive.
- Question 4** Point to the acetowhite lesion(s) on the cervix.
The lesion is identified above.
- Question 5** Is this patient a good candidate for cryotherapy?
Yes.

Funding provided by the Bill & Melinda Gates Foundation through the Alliance for Cervical Cancer Prevention. The opinions expressed herein are those of Jhpiego.

Flash Card No. 50

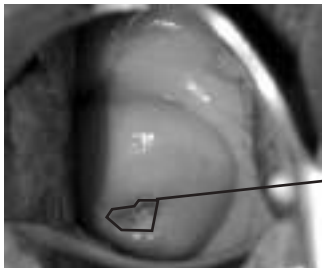


innovating to save lives



an affiliate of Johns Hopkins University

Flash Card No. 50 Answers



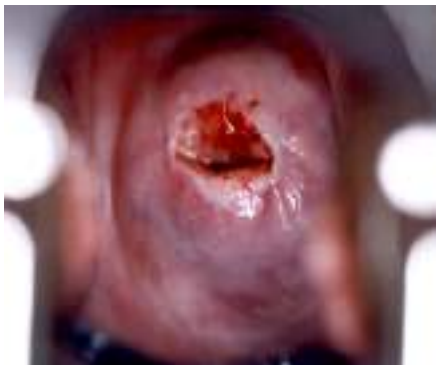SCJ

- Question 1** Is the cervix suspicious for cancer?
No.
- Question 2** If the squamocolumnar junction (SCJ) can be seen on the cervix, point to it.
The SCJ is identified above.
- Question 3** Is the cervix VIA-positive or VIA-negative?
VIA-negative.

[Answer to Q3 is “VIA-negative,” so Q4–5 are skipped.]

Funding provided by the Bill & Melinda Gates Foundation through the Alliance for Cervical Cancer Prevention. The opinions expressed herein are those of Jhpiego.

Flash Card No. 51



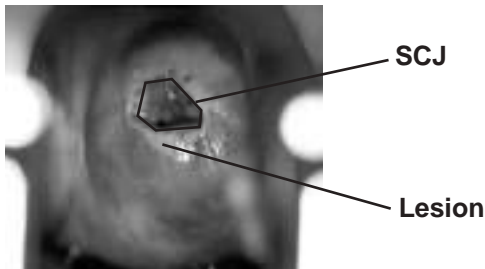
innovating to save lives



an affiliate of Johns Hopkins University



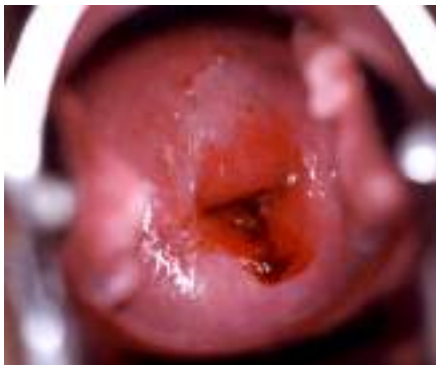Flash Card No. 51 Answers



- Question 1** Is the cervix suspicious for cancer?
No.
- Question 2** If the squamocolumnar junction (SCJ) can be seen on the cervix, point to it.
The SCJ is identified above.
- Question 3** Is the cervix VIA-positive or VIA-negative?
VIA-positive.
- Question 4** Point to the acetowhite lesion(s) on the cervix.
The lesions are identified above.
- Question 5** Is this patient a good candidate for cryotherapy?
Yes.

Funding provided by the Bill & Melinda Gates Foundation through the Alliance for Cervical Cancer Prevention. The opinions expressed herein are those of Jhpiego.

Flash Card No. 52

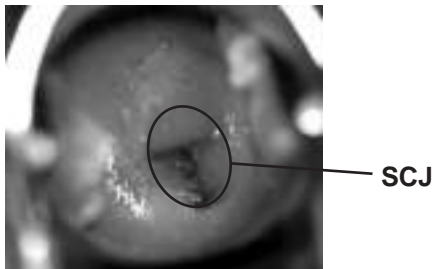


innovating to save lives



an affiliate of Johns Hopkins University

Flash Card No. 52 Answers

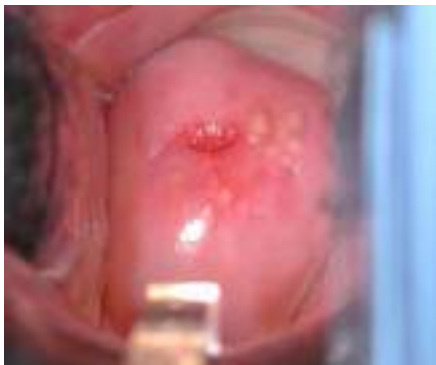

- Question 1** Is the cervix suspicious for cancer?
No.
- Question 2** If the squamocolumnar junction (SCJ) can be seen on the cervix, point to it.
The SCJ is identified above.
- Question 3** Is the cervix VIA-positive or VIA-negative?
VIA-negative.

[Answer to Q3 is “VIA-negative,” so Q4–5 are skipped.]

Funding provided by the Bill & Melinda Gates Foundation through the Alliance for Cervical Cancer Prevention. The opinions expressed herein are those of Jhpiego.

Flash Card No. 53




innovating to save lives



an affiliate of Johns Hopkins University

Flash Card No. 53 Answers

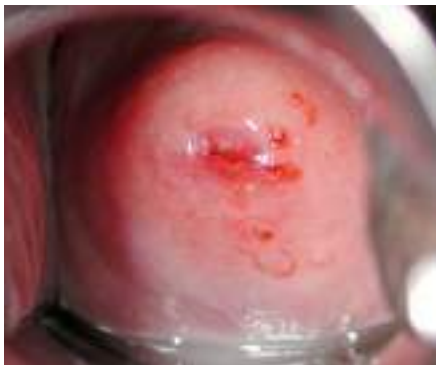

- Question 1** Is the cervix suspicious for cancer?
No.
- Question 2** If the squamocolumnar junction (SCJ) can be seen on the cervix, point to it.
The SCJ is identified above.
- Question 3** Is the cervix VIA-positive or VIA-negative?
VIA-negative.

[Answer to Q3 is “VIA-negative,” so Q4–5 are skipped.]

Funding provided by the Bill & Melinda Gates Foundation through the Alliance for Cervical Cancer Prevention. The opinions expressed herein are those of Jhpiego.

Flash Card No. 54

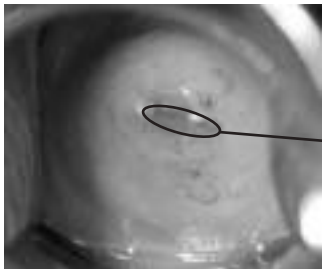


innovating to save lives



an affiliate of Johns Hopkins University

Flash Card No. 54 Answers



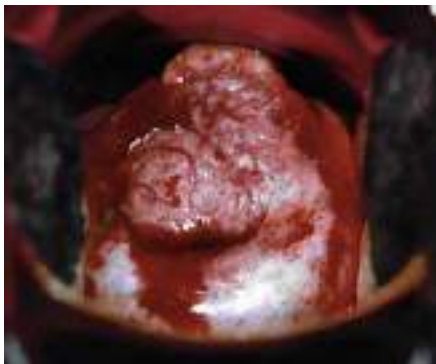SCJ

- Question 1** Is the cervix suspicious for cancer?
No.
- Question 2** If the squamocolumnar junction (SCJ) can be seen on the cervix, point to it.
The SCJ is identified above.
- Question 3** Is the cervix VIA-positive or VIA-negative?
VIA-negative.

[Answer to Q3 is “VIA-negative,” so Q4–5 are skipped.]

Funding provided by the Bill & Melinda Gates Foundation through the Alliance for Cervical Cancer Prevention. The opinions expressed herein are those of Jhpiego.

Flash Card No. 55

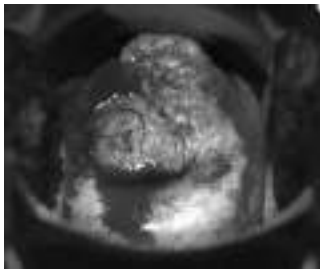


innovating to save lives



an affiliate of Johns Hopkins University

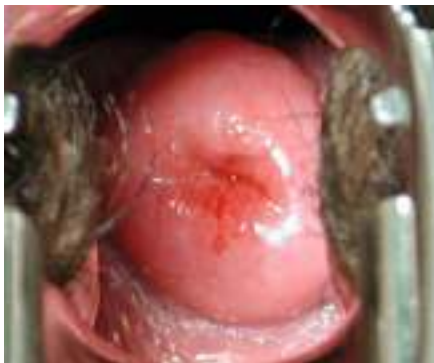Flash Card No. 55 Answers



- Question 1** Is the cervix suspicious for cancer?
Yes.
- Question 2** If the squamocolumnar junction (SCJ) can be seen on the cervix, point to it.
The SCJ is not visible.
- Question 3** Is the cervix VIA-positive or VIA-negative?
VIA-positive.
- Question 4** Point to the acetowhite lesion(s) on the cervix.
The whole cervix is affected.
- Question 5** Is this patient a good candidate for cryotherapy?
No, because the cervix is suspicious for cancer.

Funding provided by the Bill & Melinda Gates Foundation through the Alliance for Cervical Cancer Prevention. The opinions expressed herein are those of Jhpiego.

Flash Card No. 56

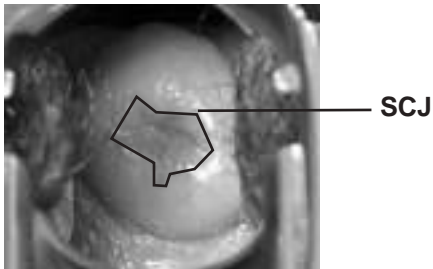


innovating to save lives



an affiliate of Johns Hopkins University

Flash Card No. 56 Answers

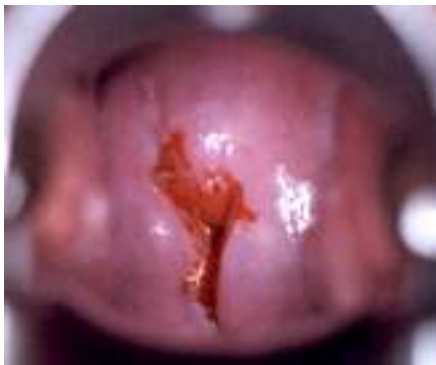

- Question 1** Is the cervix suspicious for cancer?
No.
- Question 2** If the squamocolumnar junction (SCJ) can be seen on the cervix, point to it.
The SCJ is identified above.
- Question 3** Is the cervix VIA-positive or VIA-negative?
VIA-negative.

[Answer to Q3 is “VIA-negative,” so Q4–5 are skipped.]

Funding provided by the Bill & Melinda Gates Foundation through the Alliance for Cervical Cancer Prevention. The opinions expressed herein are those of Jhpiego.

Flash Card No. 57

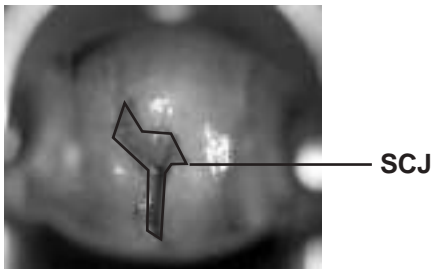


innovating to save lives



an affiliate of Johns Hopkins University

Flash Card No. 57 Answers

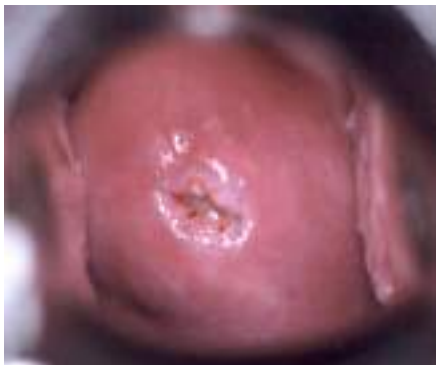

- Question 1** Is the cervix suspicious for cancer?
No.
- Question 2** If the squamocolumnar junction (SCJ) can be seen on the cervix, point to it.
The SCJ is identified above.
- Question 3** Is the cervix VIA-positive or VIA-negative?
VIA-negative.

[Answer to Q3 is “VIA-negative,” so Q4–5 are skipped.]

Funding provided by the Bill & Melinda Gates Foundation through the Alliance for Cervical Cancer Prevention. The opinions expressed herein are those of Jhpiego.

Flash Card No. 58

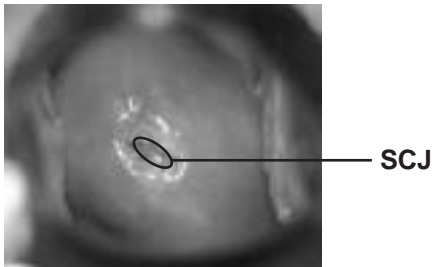


innovating to save lives



an affiliate of Johns Hopkins University

Flash Card No. 58 Answers

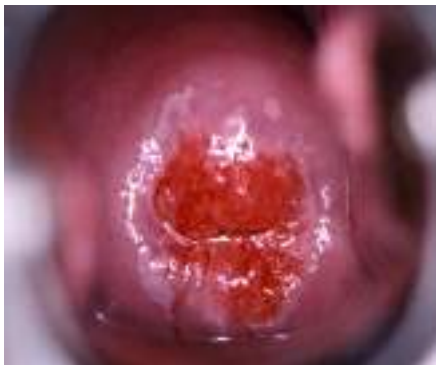

- Question 1** Is the cervix suspicious for cancer?
No.
- Question 2** If the squamocolumnar junction (SCJ) can be seen on the cervix, point to it.
The SCJ is identified above.
- Question 3** Is the cervix VIA-positive or VIA-negative?
VIA-negative.

[Answer to Q3 is “VIA-negative,” so Q4–5 are skipped.]

Funding provided by the Bill & Melinda Gates Foundation through the Alliance for Cervical Cancer Prevention. The opinions expressed herein are those of Jhpiego.

Flash Card No. 59



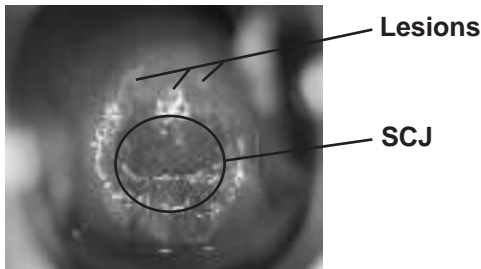
innovating to save lives



an affiliate of Johns Hopkins University



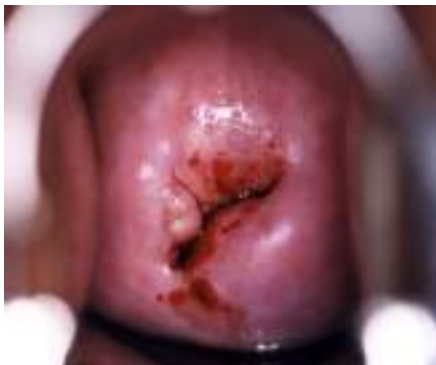Flash Card No. 59 Answers



- Question 1** Is the cervix suspicious for cancer?
No.
- Question 2** If the squamocolumnar junction (SCJ) can be seen on the cervix, point to it.
The SCJ is identified above.
- Question 3** Is the cervix VIA-positive or VIA-negative?
VIA-positive.
- Question 4** Point to the acetowhite lesion(s) on the cervix.
The lesions are identified above.
- Question 5** Is this patient a good candidate for cryotherapy?
Yes.

Funding provided by the Bill & Melinda Gates Foundation through the Alliance for Cervical Cancer Prevention. The opinions expressed herein are those of Jhpiego.

Flash Card No. 60




innovating to save lives



an affiliate of Johns Hopkins University



Flash Card No. 60 Answers

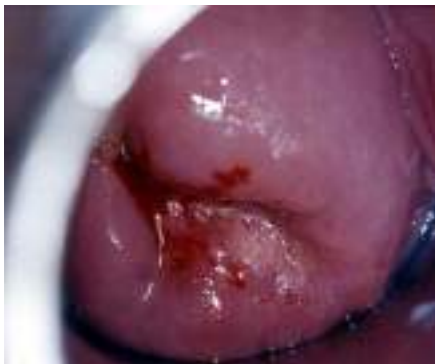

- Question 1** Is the cervix suspicious for cancer?
No.
- Question 2** If the squamocolumnar junction (SCJ) can be seen on the cervix, point to it.
The SCJ is identified above.
- Question 3** Is the cervix VIA-positive or VIA-negative?
VIA-negative.

[Answer to Q3 is “VIA-negative,” so Q4–5 are skipped.]

Funding provided by the Bill & Melinda Gates Foundation through the Alliance for Cervical Cancer Prevention. The opinions expressed herein are those of Jhpiego.

Flash Card No. 61



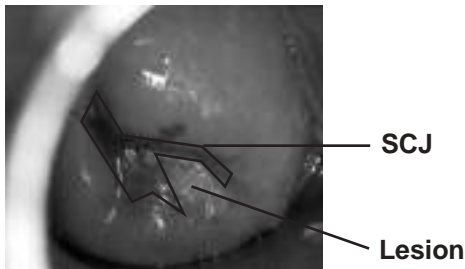
innovating to save lives



an affiliate of Johns Hopkins University



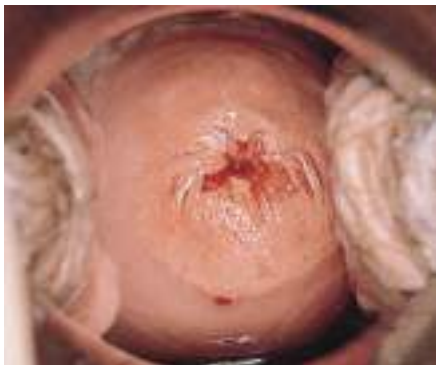Flash Card No. 61 Answers



- Question 1** Is the cervix suspicious for cancer?
No.
- Question 2** If the squamocolumnar junction (SCJ) can be seen on the cervix, point to it.
The SCJ is identified above.
- Question 3** Is the cervix VIA-positive or VIA-negative?
VIA-positive.
- Question 4** Point to the acetowhite lesion(s) on the cervix.
The lesion is identified above.
- Question 5** Is this patient a good candidate for cryotherapy?
Yes.

Funding provided by the Bill & Melinda Gates Foundation through the Alliance for Cervical Cancer Prevention. The opinions expressed herein are those of Jhpiego.

Flash Card No. 62

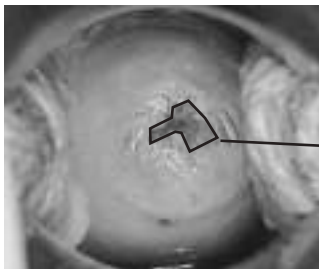


innovating to save lives



an affiliate of Johns Hopkins University

Flash Card No. 62 Answers



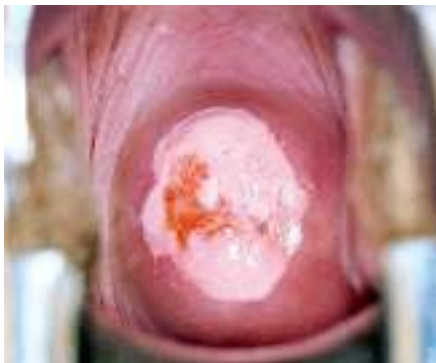SCJ

- Question 1** Is the cervix suspicious for cancer?
No.
- Question 2** If the squamocolumnar junction (SCJ) can be seen on the cervix, point to it.
The SCJ is identified above.
- Question 3** Is the cervix VIA-positive or VIA-negative?
VIA-negative.

[Answer to Q3 is “VIA-negative,” so Q4–5 are skipped.]

Funding provided by the Bill & Melinda Gates Foundation through the Alliance for Cervical Cancer Prevention. The opinions expressed herein are those of Jhpiego.

Flash Card No. 63

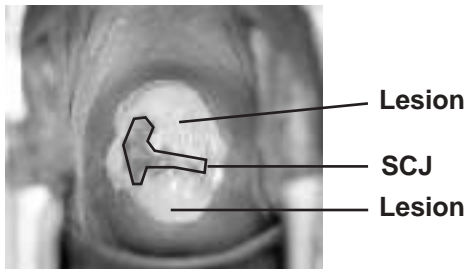


innovating to save lives



an affiliate of Johns Hopkins University

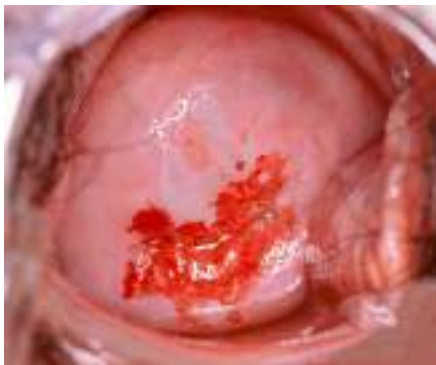Flash Card No. 63 Answers



- Question 1** Is the cervix suspicious for cancer?
No.
- Question 2** If the squamocolumnar junction (SCJ) can be seen on the cervix, point to it.
The SCJ is identified above.
- Question 3** Is the cervix VIA-positive or VIA-negative?
VIA-positive.
- Question 4** Point to the acetowhite lesion(s) on the cervix.
The lesions are identified above.
- Question 5** Is this patient a good candidate for cryotherapy?
No. (In this image the cervix appears small but because the lesion extends too far on the cervix, it will not be completely covered by a standard cryoprobe.)

Funding provided by the Bill & Melinda Gates Foundation through the Alliance for Cervical Cancer Prevention. The opinions expressed herein are those of Jhpiego.

Flash Card No. 64



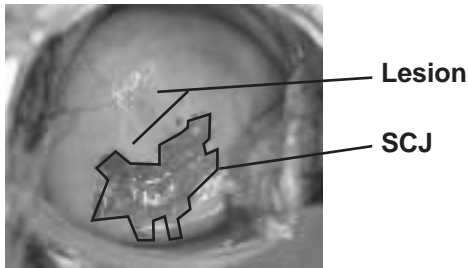
innovating to save lives



an affiliate of Johns Hopkins University



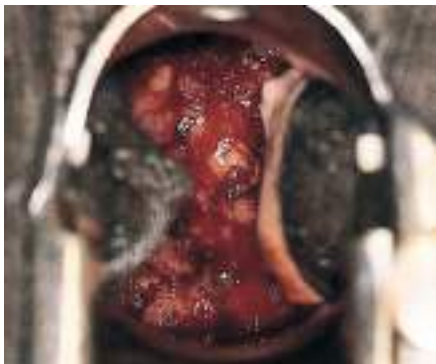Flash Card No. 64 Answers



- Question 1** Is the cervix suspicious for cancer?
No.
- Question 2** If the squamocolumnar junction (SCJ) can be seen on the cervix, point to it.
The SCJ is identified above.
- Question 3** Is the cervix VIA-positive or VIA-negative?
VIA-positive.
- Question 4** Point to the acetowhite lesion(s) on the cervix.
The lesion is identified above.
- Question 5** Is this patient a good candidate for cryotherapy?
Yes.

Funding provided by the Bill & Melinda Gates Foundation through the Alliance for Cervical Cancer Prevention. The opinions expressed herein are those of Jhpiego.

Flash Card No. 65

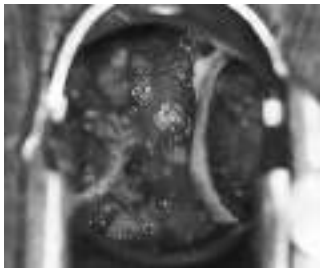


innovating to save lives



an affiliate of Johns Hopkins University

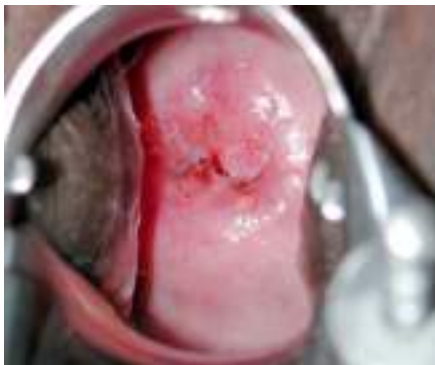Flash Card No. 65 Answers



- Question 1** Is the cervix suspicious for cancer?
Yes.
- Question 2** If the squamocolumnar junction (SCJ) can be seen on the cervix, point to it.
The SCJ is not visible.
- Question 3** Is the cervix VIA-positive or VIA-negative?
VIA-positive.
- Question 4** Point to the acetowhite lesion(s) on the cervix.
The whole cervix is affected.
- Question 5** Is this patient a good candidate for cryotherapy?
No, because the cervix is suspicious for cancer.

Funding provided by the Bill & Melinda Gates Foundation through the Alliance for Cervical Cancer Prevention. The opinions expressed herein are those of Jhpiego.

Flash Card No. 66

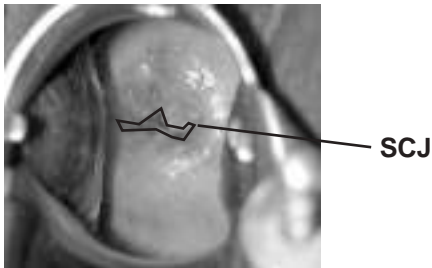


innovating to save lives



an affiliate of Johns Hopkins University

Flash Card No. 66 Answers

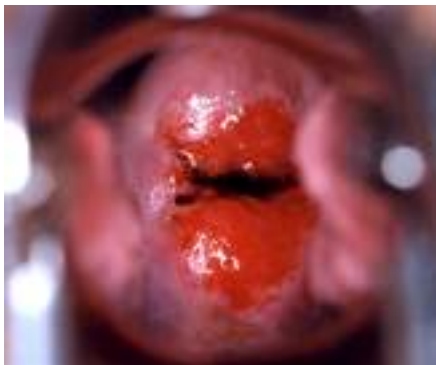

- Question 1** Is the cervix suspicious for cancer?
No.
- Question 2** If the squamocolumnar junction (SCJ) can be seen on the cervix, point to it.
The SCJ is identified above.
- Question 3** Is the cervix VIA-positive or VIA-negative?
VIA-negative.

[Answer to Q3 is “VIA-negative,” so Q4–5 are skipped.]

Funding provided by the Bill & Melinda Gates Foundation through the Alliance for Cervical Cancer Prevention. The opinions expressed herein are those of Jhpiego.

Flash Card No. 67

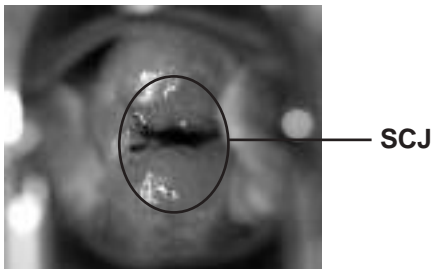


innovating to save lives



an affiliate of Johns Hopkins University

Flash Card No. 67 Answers

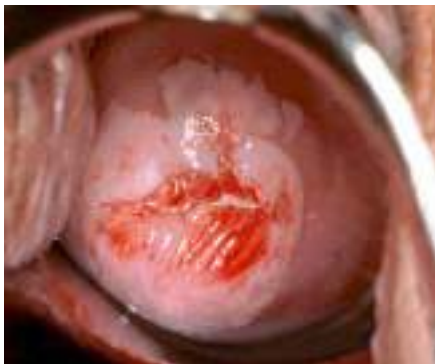

- Question 1** Is the cervix suspicious for cancer?
No.
- Question 2** If the squamocolumnar junction (SCJ) can be seen on the cervix, point to it.
The SCJ is identified above.
- Question 3** Is the cervix VIA-positive or VIA-negative?
VIA-negative.

[Answer to Q3 is “VIA-negative,” so Q4–5 are skipped.]

Funding provided by the Bill & Melinda Gates Foundation through the Alliance for Cervical Cancer Prevention. The opinions expressed herein are those of Jhpiego.

Flash Card No. 68



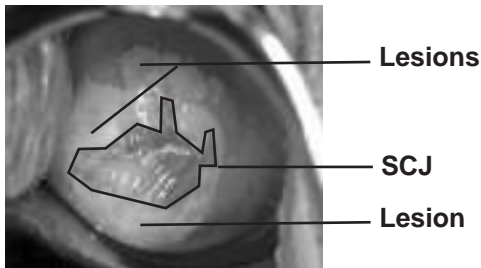
innovating to save lives



an affiliate of Johns Hopkins University



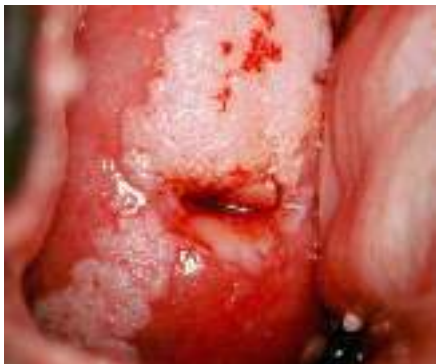Flash Card No. 68 Answers



- Question 1** Is the cervix suspicious for cancer?
No.
- Question 2** If the squamocolumnar junction (SCJ) can be seen on the cervix, point to it.
The SCJ is identified above.
- Question 3** Is the cervix VIA-positive or VIA-negative?
VIA-positive.
- Question 4** Point to the acetowhite lesion(s) on the cervix.
The lesions are identified above.
- Question 5** Is this patient a good candidate for cryotherapy?
No. The lesions extend too far on the cervix (will not be covered by cryoprobe).

Funding provided by the Bill & Melinda Gates Foundation through the Alliance for Cervical Cancer Prevention. The opinions expressed herein are those of Jhpiego.

Flash Card No. 69



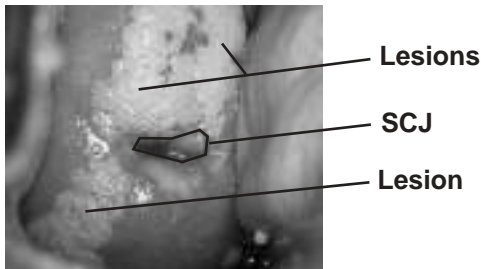
innovating to save lives



an affiliate of Johns Hopkins University



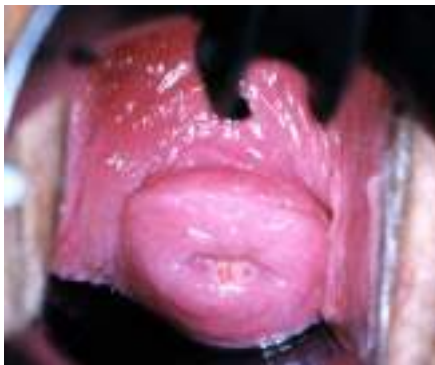Flash Card No. 69 Answers



- Question 1** Is the cervix suspicious for cancer?
No.
- Question 2** If the squamocolumnar junction (SCJ) can be seen on the cervix, point to it.
The SCJ is identified above.
- Question 3** Is the cervix VIA-positive or VIA-negative?
VIA-positive.
- Question 4** Point to the acetowhite lesion(s) on the cervix.
The lesions are identified above.
- Question 5** Is this patient a good candidate for cryotherapy?
No. The lesions extend too far on the cervix (will not be covered by cryoprobe).

Funding provided by the Bill & Melinda Gates Foundation through the Alliance for Cervical Cancer Prevention. The opinions expressed herein are those of Jhpiego.

Flash Card No. 70



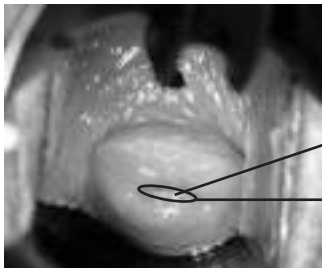
innovating to save lives



an affiliate of Johns Hopkins University



Flash Card No. 70 Answers



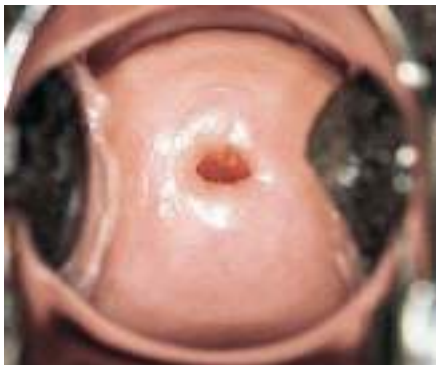Lesion

SCJ

- Question 1** Is the cervix suspicious for cancer?
No.
- Question 2** If the squamocolumnar junction (SCJ) can be seen on the cervix, point to it.
The SCJ is identified above.
- Question 3** Is the cervix VIA-positive or VIA-negative?
VIA-positive.
- Question 4** Point to the acetowhite lesion(s) on the cervix.
The lesion is identified above.
- Question 5** Is this patient a good candidate for cryotherapy?
Yes.

Funding provided by the Bill & Melinda Gates Foundation through the Alliance for Cervical Cancer Prevention. The opinions expressed herein are those of Jhpiego.

Flash Card No. 71

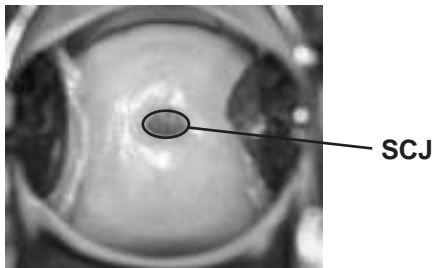


innovating to save lives



an affiliate of Johns Hopkins University

Flash Card No. 71 Answers

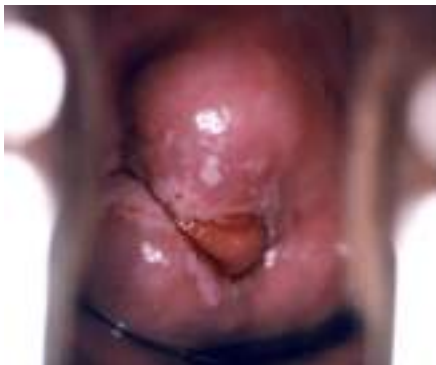

- Question 1** Is the cervix suspicious for cancer?
No.
- Question 2** If the squamocolumnar junction (SCJ) can be seen on the cervix, point to it.
The SCJ is identified above.
- Question 3** Is the cervix VIA-positive or VIA-negative?
VIA-negative.

[Answer to Q3 is “VIA-negative,” so Q4–5 are skipped.]

Funding provided by the Bill & Melinda Gates Foundation through the Alliance for Cervical Cancer Prevention. The opinions expressed herein are those of Jhpiego.

Flash Card No. 72



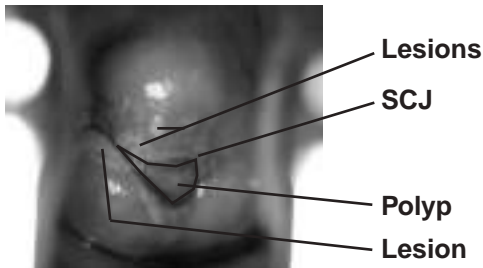
innovating to save lives



an affiliate of Johns Hopkins University



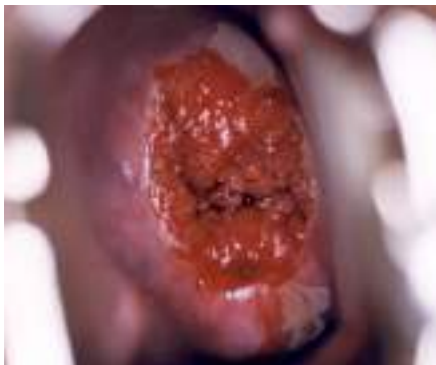Flash Card No. 72 Answers



- Question 1** Is the cervix suspicious for cancer?
No.
- Question 2** If the squamocolumnar junction (SCJ) can be seen on the cervix, point to it.
The SCJ is identified above.
- Question 3** Is the cervix VIA-positive or VIA-negative?
VIA-positive.
- Question 4** Point to the acetowhite lesion(s) on the cervix.
The lesions are identified above.
- Question 5** Is this patient a good candidate for cryotherapy?
Yes.

Funding provided by the Bill & Melinda Gates Foundation through the Alliance for Cervical Cancer Prevention. The opinions expressed herein are those of Jhpiego.

Flash Card No. 73



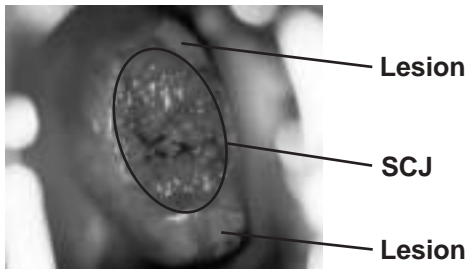
innovating to save lives



an affiliate of Johns Hopkins University



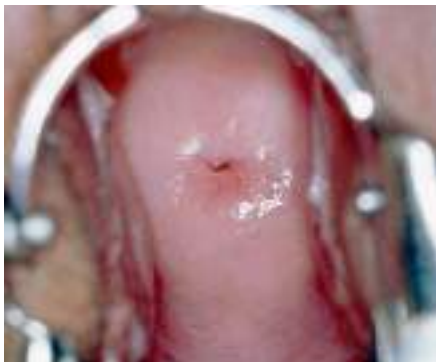Flash Card No. 73 Answers



- Question 1** Is the cervix suspicious for cancer?
No.
- Question 2** If the squamocolumnar junction (SCJ) can be seen on the cervix, point to it.
The SCJ is identified above.
- Question 3** Is the cervix VIA-positive or VIA-negative?
VIA-positive.
- Question 4** Point to the acetowhite lesion(s) on the cervix.
The lesions are identified above.
- Question 5** Is this patient a good candidate for cryotherapy?
No. The lesions extend too far on the cervix (will not be covered by cryoprobe).

Funding provided by the Bill & Melinda Gates Foundation through the Alliance for Cervical Cancer Prevention. The opinions expressed herein are those of Jhpiego.

Flash Card No. 74

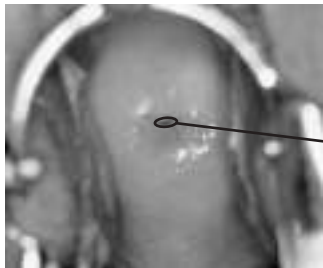

innovating to save lives



an affiliate of Johns Hopkins University

Flash Card No. 74 Answers



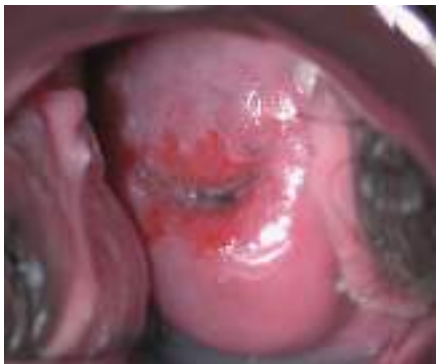SCJ

- Question 1** Is the cervix suspicious for cancer?
No.
- Question 2** If the squamocolumnar junction (SCJ) can be seen on the cervix, point to it.
The SCJ is identified above.
- Question 3** Is the cervix VIA-positive or VIA-negative?
VIA-negative.

[Answer to Q3 is “VIA-negative,” so Q4–5 are skipped.]

Funding provided by the Bill & Melinda Gates Foundation through the Alliance for Cervical Cancer Prevention. The opinions expressed herein are those of Jhpiego.

Flash Card No. 75

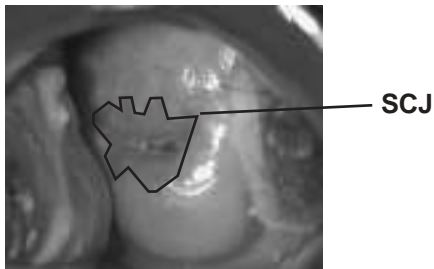


innovating to save lives



an affiliate of Johns Hopkins University

Flash Card No. 75 Answers

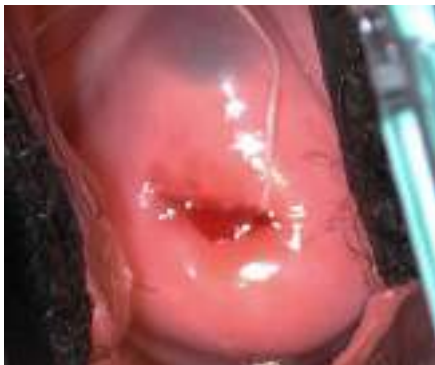

- Question 1** Is the cervix suspicious for cancer?
No.
- Question 2** If the squamocolumnar junction (SCJ) can be seen on the cervix, point to it.
The SCJ is identified above.
- Question 3** Is the cervix VIA-positive or VIA-negative?
VIA-negative.

[Answer to Q3 is “VIA-negative,” so Q4–5 are skipped.]

Funding provided by the Bill & Melinda Gates Foundation through the Alliance for Cervical Cancer Prevention. The opinions expressed herein are those of Jhpiego.

Flash Card No. 76

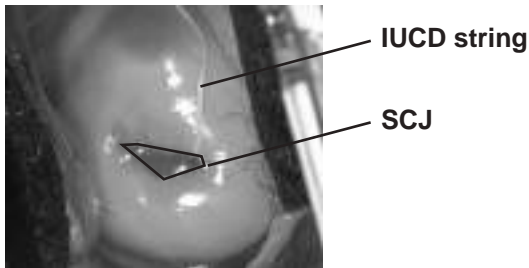


innovating to save lives



an affiliate of Johns Hopkins University

Flash Card No. 76 Answers



Question 1 Is the cervix suspicious for cancer?
No.

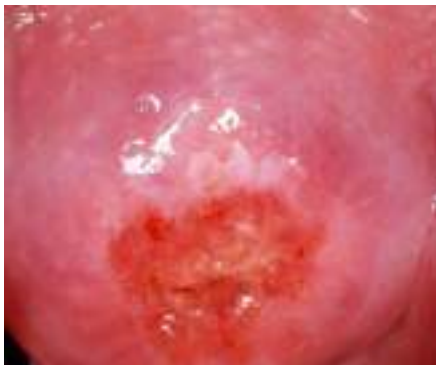Question 2 If the squamocolumnar junction (SCJ) can be seen on the cervix, point to it.
The SCJ is identified above.

Question 3 Is the cervix VIA-positive or VIA-negative?
VIA-negative.

[Answer to Q3 is “VIA-negative,” so Q4–5 are skipped.]

Funding provided by the Bill & Melinda Gates Foundation through the Alliance for Cervical Cancer Prevention. The opinions expressed herein are those of Jhpiego.

Flash Card No. 77




innovating to save lives



an affiliate of Johns Hopkins University



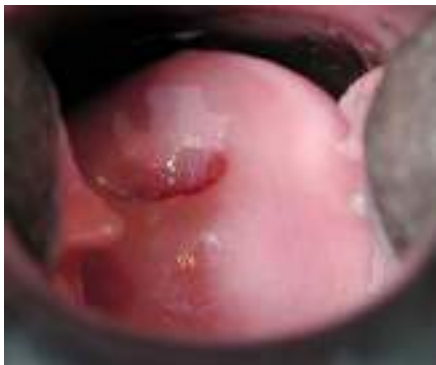Flash Card No. 77 Answers



- Question 1** Is the cervix suspicious for cancer?
No.
- Question 2** If the squamocolumnar junction (SCJ) can be seen on the cervix, point to it.
The SCJ is identified above.
- Question 3** Is the cervix VIA-positive or VIA-negative?
VIA-positive.
- Question 4** Point to the acetowhite lesion(s) on the cervix.
The lesion is identified above.
- Question 5** Is this patient a good candidate for cryotherapy?
Yes.

Funding provided by the Bill & Melinda Gates Foundation through the Alliance for Cervical Cancer Prevention. The opinions expressed herein are those of Jhpiego.

Flash Card No. 78



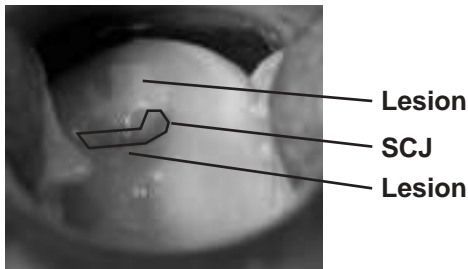
innovating to save lives



an affiliate of Johns Hopkins University



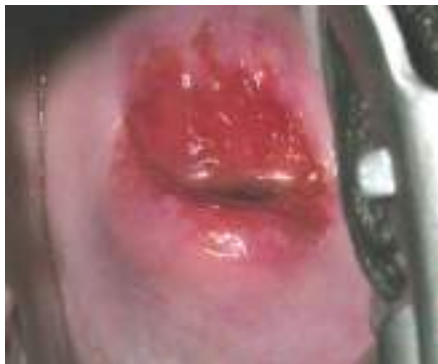Flash Card No. 78 Answers



- Question 1** Is the cervix suspicious for cancer?
No.
- Question 2** If the squamocolumnar junction (SCJ) can be seen on the cervix, point to it.
The SCJ is identified above.
- Question 3** Is the cervix VIA-positive or VIA-negative?
VIA-positive.
- Question 4** Point to the acetowhite lesion(s) on the cervix.
The lesions are identified above.
- Question 5** Is this patient a good candidate for cryotherapy?
Yes.

Funding provided by the Bill & Melinda Gates Foundation through the Alliance for Cervical Cancer Prevention. The opinions expressed herein are those of Jhpiego.

Flash Card No. 79

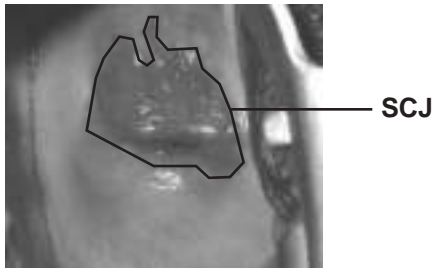


innovating to save lives



an affiliate of Johns Hopkins University

Flash Card No. 79 Answers

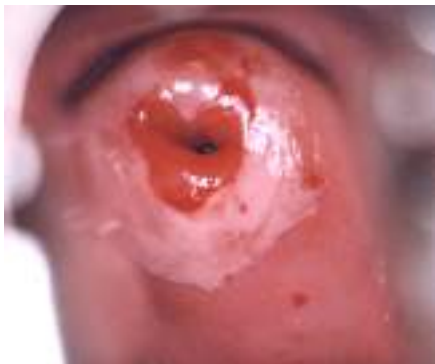

- Question 1** Is the cervix suspicious for cancer?
No.
- Question 2** If the squamocolumnar junction (SCJ) can be seen on the cervix, point to it.
The SCJ is identified above.
- Question 3** Is the cervix VIA-positive or VIA-negative?
VIA-negative.

[Answer to Q3 is “VIA-negative,” so Q4–5 are skipped.]

Funding provided by the Bill & Melinda Gates Foundation through the Alliance for Cervical Cancer Prevention. The opinions expressed herein are those of Jhpiego.

Flash Card No. 80



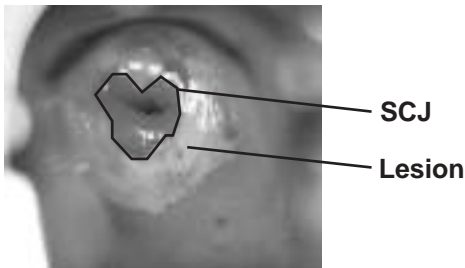
innovating to save lives



an affiliate of Johns Hopkins University



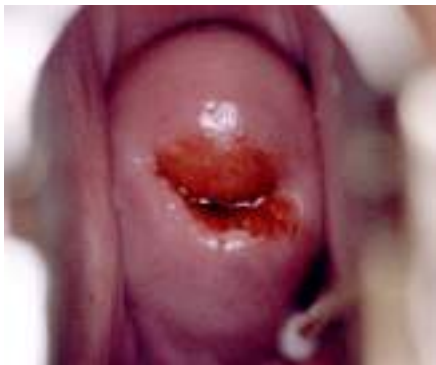Flash Card No. 80 Answers



- Question 1** Is the cervix suspicious for cancer?
No.
- Question 2** If the squamocolumnar junction (SCJ) can be seen on the cervix, point to it.
The SCJ is identified above.
- Question 3** Is the cervix VIA-positive or VIA-negative?
VIA-positive.
- Question 4** Point to the acetowhite lesion(s) on the cervix.
The lesion is identified above.
- Question 5** Is this patient a good candidate for cryotherapy?
Yes.

Funding provided by the Bill & Melinda Gates Foundation through the Alliance for Cervical Cancer Prevention. The opinions expressed herein are those of Jhpiego.

Flash Card No. 81



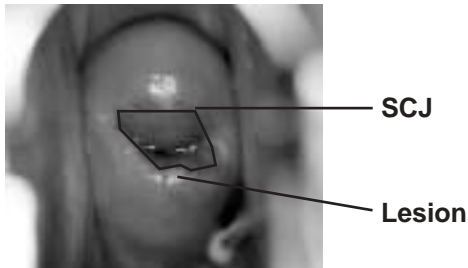
innovating to save lives



an affiliate of Johns Hopkins University



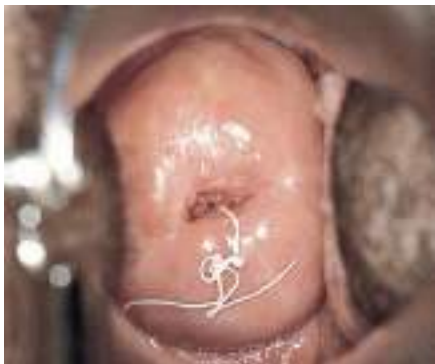Flash Card No. 81 Answers



- Question 1** Is the cervix suspicious for cancer?
No.
- Question 2** If the squamocolumnar junction (SCJ) can be seen on the cervix, point to it.
The SCJ is identified above.
- Question 3** Is the cervix VIA-positive or VIA-negative?
VIA-positive.
- Question 4** Point to the acetowhite lesion(s) on the cervix.
The lesion is identified above. (The lesion is small with defined borders and at the SCJ.)
- Question 5** Is this patient a good candidate for cryotherapy?
Yes.

Funding provided by the Bill & Melinda Gates Foundation through the Alliance for Cervical Cancer Prevention. The opinions expressed herein are those of Jhpiego.

Flash Card No. 82

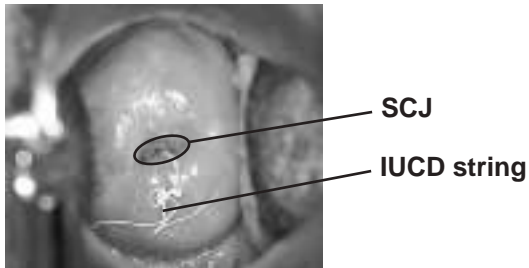


innovating to save lives



an affiliate of Johns Hopkins University

Flash Card No. 82 Answers



Question 1 Is the cervix suspicious for cancer?
No.

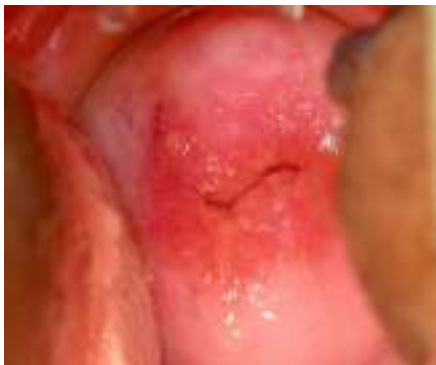Question 2 If the squamocolumnar junction (SCJ) can be seen on the cervix, point to it.
The SCJ is identified above.

Question 3 Is the cervix VIA-positive or VIA-negative?
VIA-negative.

[Answer to Q3 is “VIA-negative,” so Q4–5 are skipped.]

Funding provided by the Bill & Melinda Gates Foundation through the Alliance for Cervical Cancer Prevention. The opinions expressed herein are those of Jhpiego.

Flash Card No. 83

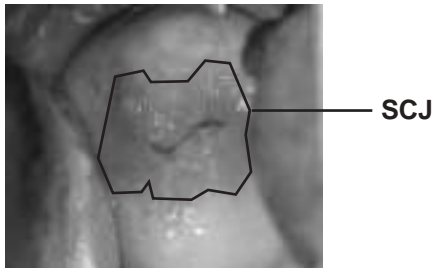


innovating to save lives



an affiliate of Johns Hopkins University

Flash Card No. 83 Answers

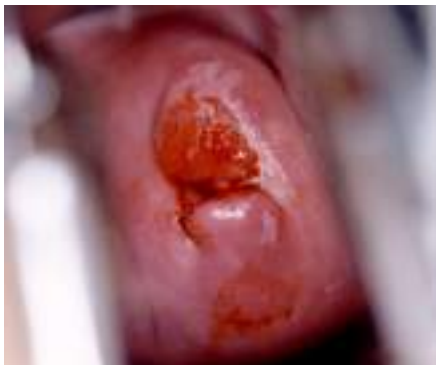

- Question 1** Is the cervix suspicious for cancer?
No.
- Question 2** If the squamocolumnar junction (SCJ) can be seen on the cervix, point to it.
The SCJ is identified above.
- Question 3** Is the cervix VIA-positive or VIA-negative?
VIA-negative.

[Answer to Q3 is “VIA-negative,” so Q4–5 are skipped.]

Funding provided by the Bill & Melinda Gates Foundation through the Alliance for Cervical Cancer Prevention. The opinions expressed herein are those of Jhpiego.

Flash Card No. 84



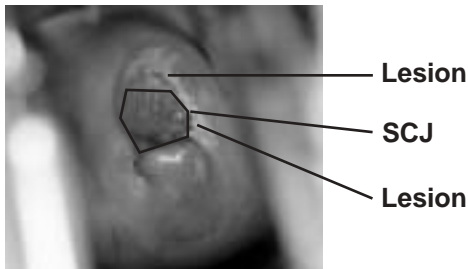
innovating to save lives



an affiliate of Johns Hopkins University



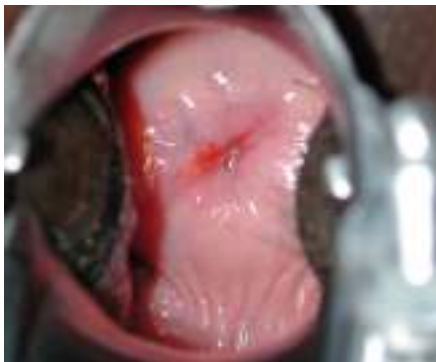Flash Card No. 84 Answers



- Question 1** Is the cervix suspicious for cancer?
No.
- Question 2** If the squamocolumnar junction (SCJ) can be seen on the cervix, point to it.
The SCJ is identified above.
- Question 3** Is the cervix VIA-positive or VIA-negative?
VIA-positive.
- Question 4** Point to the acetowhite lesion(s) on the cervix.
The lesions are identified above.
- Question 5** Is this patient a good candidate for cryotherapy?
Yes.

Funding provided by the Bill & Melinda Gates Foundation through the Alliance for Cervical Cancer Prevention. The opinions expressed herein are those of Jhpiego.

Flash Card No. 85

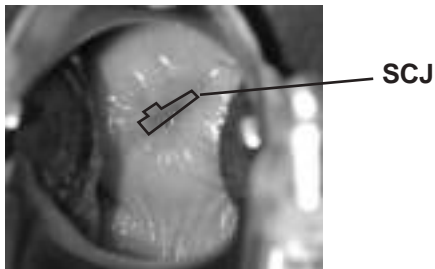


innovating to save lives



an affiliate of Johns Hopkins University

Flash Card No. 85 Answers

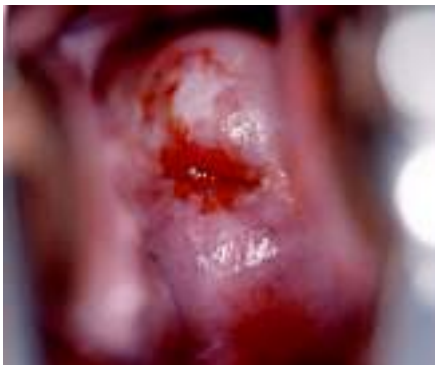

- Question 1** Is the cervix suspicious for cancer?
No.
- Question 2** If the squamocolumnar junction (SCJ) can be seen on the cervix, point to it.
The SCJ is identified above.
- Question 3** Is the cervix VIA-positive or VIA-negative?
VIA-negative.

[Answer to Q3 is “VIA-negative,” so Q4–5 are skipped.]

Funding provided by the Bill & Melinda Gates Foundation through the Alliance for Cervical Cancer Prevention. The opinions expressed herein are those of Jhpiego.

Flash Card No. 86



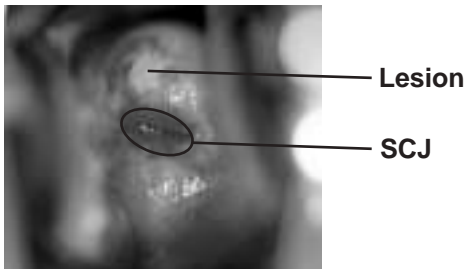
innovating to save lives



an affiliate of Johns Hopkins University



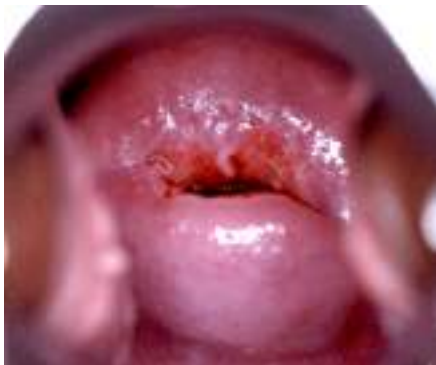Flash Card No. 86 Answers



- Question 1** Is the cervix suspicious for cancer?
No.
- Question 2** If the squamocolumnar junction (SCJ) can be seen on the cervix, point to it.
The SCJ is identified above.
- Question 3** Is the cervix VIA-positive or VIA-negative?
VIA-positive.
- Question 4** Point to the acetowhite lesion(s) on the cervix.
The lesion is identified above.
- Question 5** Is this patient a good candidate for cryotherapy?
Yes.

Funding provided by the Bill & Melinda Gates Foundation through the Alliance for Cervical Cancer Prevention. The opinions expressed herein are those of Jhpiego.

Flash Card No. 87

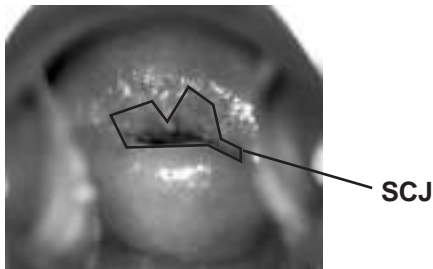


innovating to save lives



an affiliate of Johns Hopkins University

Flash Card No. 87 Answers

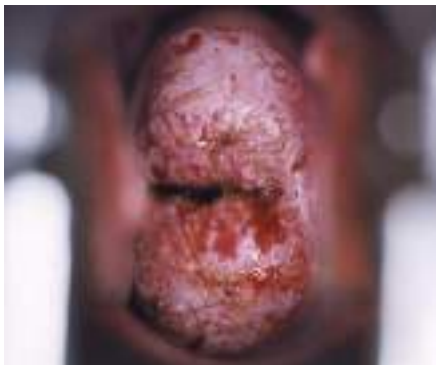

- Question 1** Is the cervix suspicious for cancer?
No.
- Question 2** If the squamocolumnar junction (SCJ) can be seen on the cervix, point to it.
The SCJ is identified above.
- Question 3** Is the cervix VIA-positive or VIA-negative?
VIA-negative.

[Answer to Q3 is “VIA-negative,” so Q4–5 are skipped.]

Funding provided by the Bill & Melinda Gates Foundation through the Alliance for Cervical Cancer Prevention. The opinions expressed herein are those of Jhpiego.

Flash Card No. 88

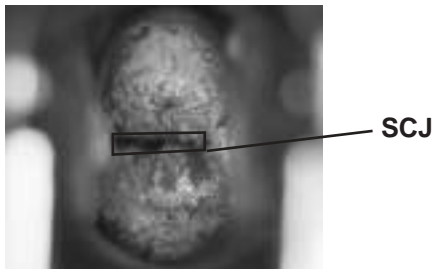


innovating to save lives



an affiliate of Johns Hopkins University

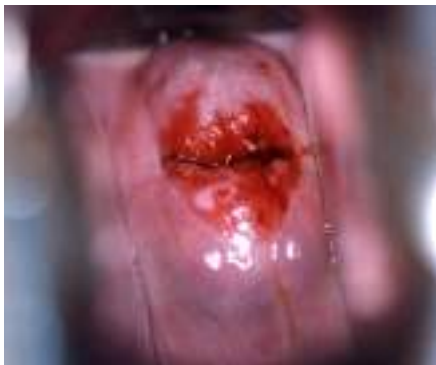Flash Card No. 88 Answers



- Question 1** Is the cervix suspicious for cancer?
Yes.
- Question 2** If the squamocolumnar junction (SCJ) can be seen on the cervix, point to it.
The SCJ is identified above.
- Question 3** Is the cervix VIA-positive or VIA-negative?
VIA-positive.
- Question 4** Point to the acetowhite lesion(s) on the cervix.
The whole cervix is affected.
- Question 5** Is this patient a good candidate for cryotherapy?
No, because the cervix is suspicious for cancer.

Funding provided by the Bill & Melinda Gates Foundation through the Alliance for Cervical Cancer Prevention. The opinions expressed herein are those of Jhpiego.

Flash Card No. 89



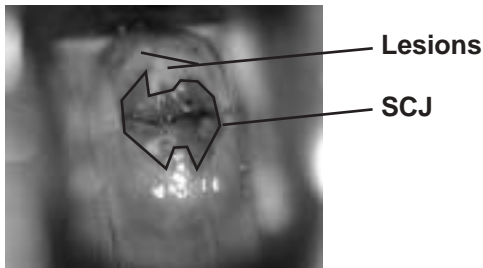
innovating to save lives



an affiliate of Johns Hopkins University



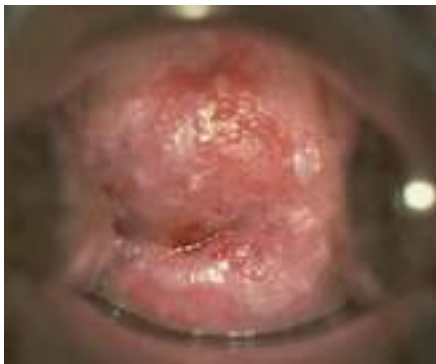Flash Card No. 89 Answers



- Question 1** Is the cervix suspicious for cancer?
No.
- Question 2** If the squamocolumnar junction (SCJ) can be seen on the cervix, point to it.
The SCJ is identified above.
- Question 3** Is the cervix VIA-positive or VIA-negative?
VIA-positive.
- Question 4** Point to the acetowhite lesion(s) on the cervix.
The lesions are identified above.
- Question 5** Is this patient a good candidate for cryotherapy?
Yes.

Funding provided by the Bill & Melinda Gates Foundation through the Alliance for Cervical Cancer Prevention. The opinions expressed herein are those of Jhpiego.

Flash Card No. 90



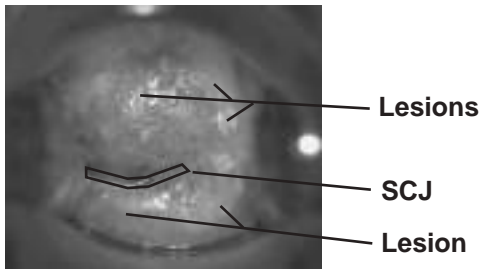
innovating to save lives



an affiliate of Johns Hopkins University



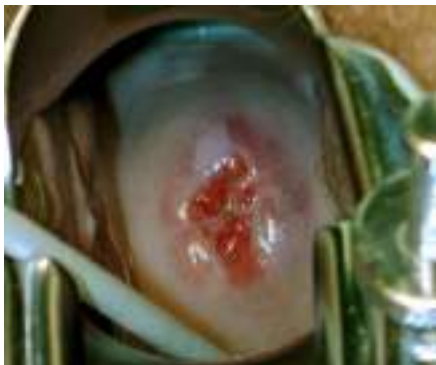Flash Card No. 90 Answers



- Question 1** Is the cervix suspicious for cancer?
No.
- Question 2** If the squamocolumnar junction (SCJ) can be seen on the cervix, point to it.
The SCJ is identified above.
- Question 3** Is the cervix VIA-positive or VIA-negative?
VIA-positive.
- Question 4** Point to the acetowhite lesion(s) on the cervix.
The lesions are identified above.
- Question 5** Is this patient a good candidate for cryotherapy?
Yes.

Funding provided by the Bill & Melinda Gates Foundation through the Alliance for Cervical Cancer Prevention. The opinions expressed herein are those of Jhpiego.

Flash Card No. 91



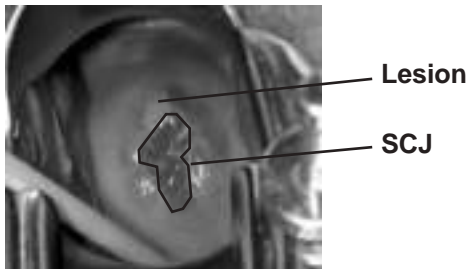
innovating to save lives



an affiliate of Johns Hopkins University



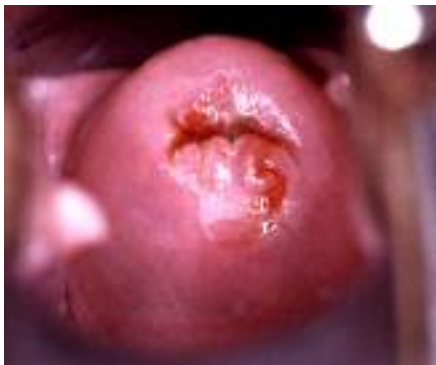Flash Card No. 91 Answers



- Question 1** Is the cervix suspicious for cancer?
No.
- Question 2** If the squamocolumnar junction (SCJ) can be seen on the cervix, point to it.
The SCJ is identified above.
- Question 3** Is the cervix VIA-positive or VIA-negative?
VIA-positive.
- Question 4** Point to the acetowhite lesion(s) on the cervix.
The lesion is identified above.
- Question 5** Is this patient a good candidate for cryotherapy?
Yes.

Funding provided by the Bill & Melinda Gates Foundation through the Alliance for Cervical Cancer Prevention. The opinions expressed herein are those of Jhpiego.

Flash Card No. 92



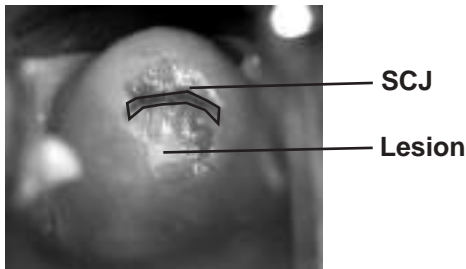
innovating to save lives



an affiliate of Johns Hopkins University



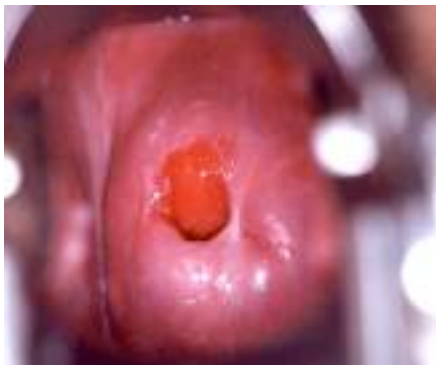Flash Card No. 92 Answers



- Question 1** Is the cervix suspicious for cancer?
No.
- Question 2** If the squamocolumnar junction (SCJ) can be seen on the cervix, point to it.
The SCJ is identified above.
- Question 3** Is the cervix VIA-positive or VIA-negative?
VIA-positive.
- Question 4** Point to the acetowhite lesion(s) on the cervix.
The lesion is identified above.
- Question 5** Is this patient a good candidate for cryotherapy?
Yes.

Funding provided by the Bill & Melinda Gates Foundation through the Alliance for Cervical Cancer Prevention. The opinions expressed herein are those of Jhpiego.

Flash Card No. 93



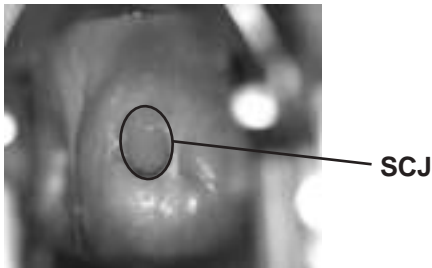
innovating to save lives



an affiliate of Johns Hopkins University



Flash Card No. 93 Answers

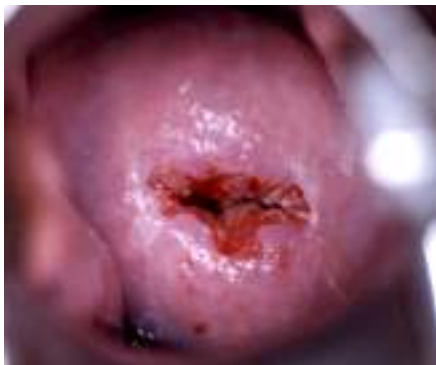

- Question 1** Is the cervix suspicious for cancer?
No.
- Question 2** If the squamocolumnar junction (SCJ) can be seen on the cervix, point to it.
The SCJ is identified above.
- Question 3** Is the cervix VIA-positive or VIA-negative?
VIA-negative.

[Answer to Q3 is “VIA-negative,” so Q4–5 are skipped.]

Funding provided by the Bill & Melinda Gates Foundation through the Alliance for Cervical Cancer Prevention. The opinions expressed herein are those of Jhpiego.

Flash Card No. 94

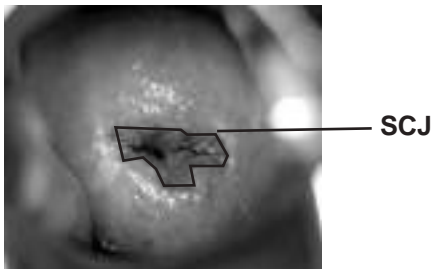


innovating to save lives



an affiliate of Johns Hopkins University

Flash Card No. 94 Answers

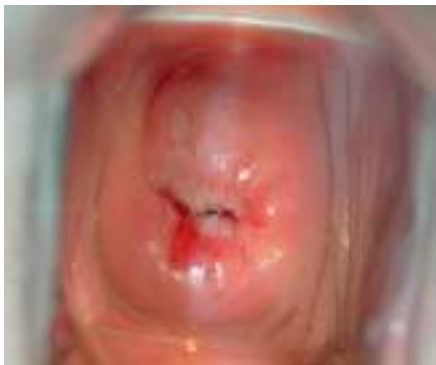

- Question 1** Is the cervix suspicious for cancer?
No.
- Question 2** If the squamocolumnar junction (SCJ) can be seen on the cervix, point to it.
The SCJ is identified above.
- Question 3** Is the cervix VIA-positive or VIA-negative?
VIA-negative.

[Answer to Q3 is “VIA-negative,” so Q4–5 are skipped.]

Funding provided by the Bill & Melinda Gates Foundation through the Alliance for Cervical Cancer Prevention. The opinions expressed herein are those of Jhpiego.

Flash Card No. 95



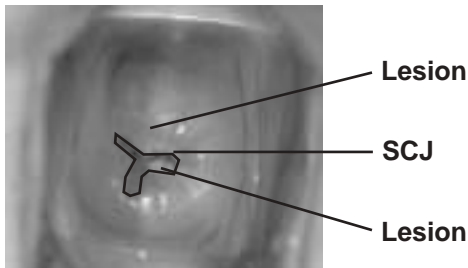
innovating to save lives



an affiliate of Johns Hopkins University



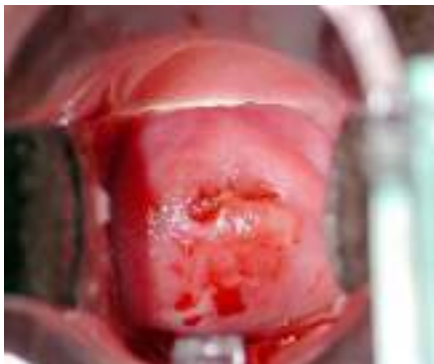Flash Card No. 95Answers



- Question 1** Is the cervix suspicious for cancer?
No.
- Question 2** If the squamocolumnar junction (SCJ) can be seen on the cervix, point to it.
The SCJ is identified above.
- Question 3** Is the cervix VIA-positive or VIA-negative?
VIA-positive.
- Question 4** Point to the acetowhite lesion(s) on the cervix.
The lesions are identified above.
- Question 5** Is this patient a good candidate for cryotherapy?
Yes.

Funding provided by the Bill & Melinda Gates Foundation through the Alliance for Cervical Cancer Prevention. The opinions expressed herein are those of Jhpiego.

Flash Card No. 96

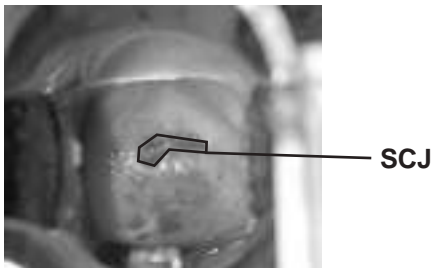


innovating to save lives



an affiliate of Johns Hopkins University

Flash Card No. 96 Answers

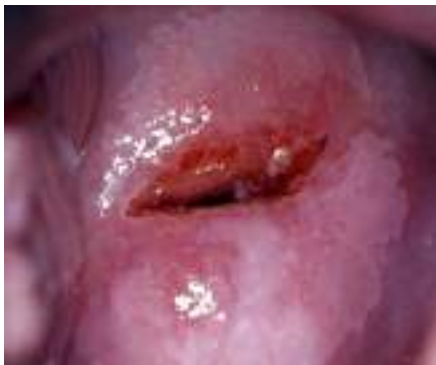

- Question 1** Is the cervix suspicious for cancer?
No.
- Question 2** If the squamocolumnar junction (SCJ) can be seen on the cervix, point to it.
The SCJ is identified above.
- Question 3** Is the cervix VIA-positive or VIA-negative?
VIA-negative.

[Answer to Q3 is “VIA-negative,” so Q4–5 are skipped.]

Funding provided by the Bill & Melinda Gates Foundation through the Alliance for Cervical Cancer Prevention. The opinions expressed herein are those of Jhpiego.

Flash Card No. 97



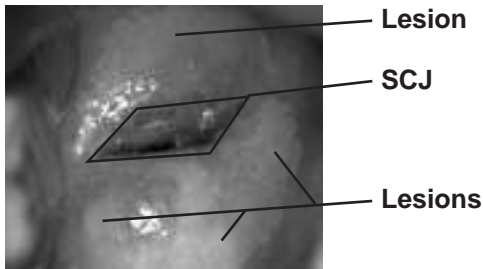
innovating to save lives



an affiliate of Johns Hopkins University



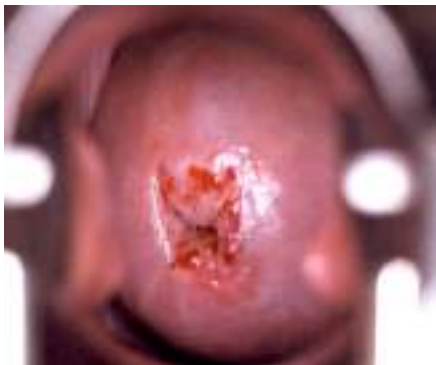Flash Card No. 97 Answers



- Question 1** Is the cervix suspicious for cancer?
No.
- Question 2** If the squamocolumnar junction (SCJ) can be seen on the cervix, point to it.
The SCJ is identified above.
- Question 3** Is the cervix VIA-positive or VIA-negative?
VIA-positive.
- Question 4** Point to the acetowhite lesion(s) on the cervix.
The lesions are identified above.
- Question 5** Is this patient a good candidate for cryotherapy?
Yes.

Funding provided by the Bill & Melinda Gates Foundation through the Alliance for Cervical Cancer Prevention. The opinions expressed herein are those of Jhpiego.

Flash Card No. 98

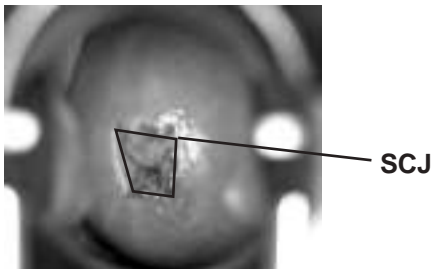


innovating to save lives



an affiliate of Johns Hopkins University

Flash Card No. 98 Answers

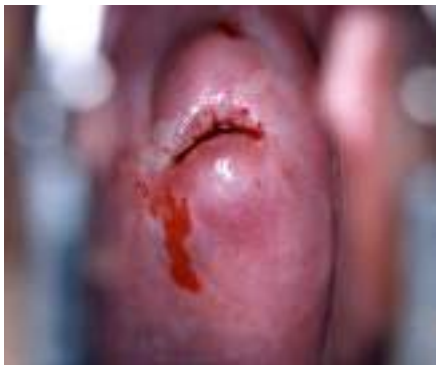

- Question 1** Is the cervix suspicious for cancer?
No.
- Question 2** If the squamocolumnar junction (SCJ) can be seen on the cervix, point to it.
The SCJ is identified above.
- Question 3** Is the cervix VIA-positive or VIA-negative?
VIA-negative.

[Answer to Q3 is “VIA-negative,” so Q4–5 are skipped.]

Funding provided by the Bill & Melinda Gates Foundation through the Alliance for Cervical Cancer Prevention. The opinions expressed herein are those of Jhpiego.

Flash Card No. 99



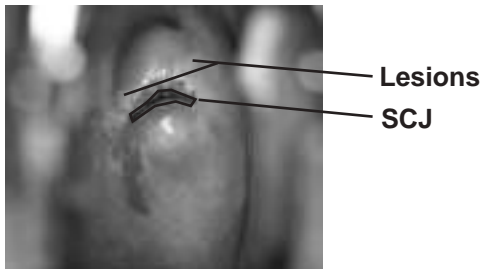
innovating to save lives



an affiliate of Johns Hopkins University



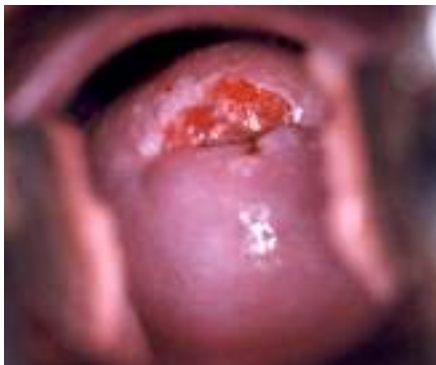Flash Card No. 99 Answers



- Question 1** Is the cervix suspicious for cancer?
No.
- Question 2** If the squamocolumnar junction (SCJ) can be seen on the cervix, point to it.
The SCJ is identified above.
- Question 3** Is the cervix VIA-positive or VIA-negative?
VIA-positive.
- Question 4** Point to the acetowhite lesion(s) on the cervix.
The lesions are identified above.
- Question 5** Is this patient a good candidate for cryotherapy?
Yes.

Funding provided by the Bill & Melinda Gates Foundation through the Alliance for Cervical Cancer Prevention. The opinions expressed herein are those of Jhpiego.

Flash Card No. 100



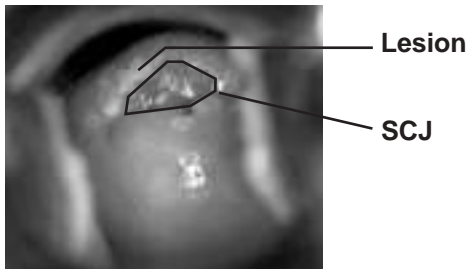
innovating to save lives



an affiliate of Johns Hopkins University



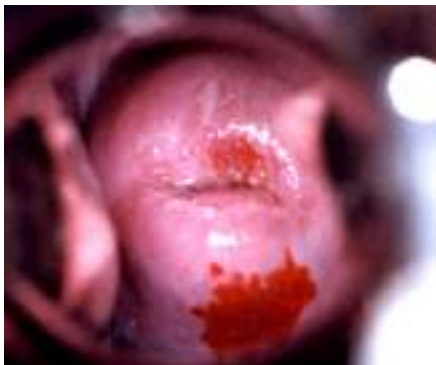Flash Card No. 100 Answers



- Question 1** Is the cervix suspicious for cancer?
No.
- Question 2** If the squamocolumnar junction (SCJ) can be seen on the cervix, point to it.
The SCJ is identified above.
- Question 3** Is the cervix VIA-positive or VIA-negative?
VIA-positive.
- Question 4** Point to the acetowhite lesion(s) on the cervix.
The lesion is identified above.
- Question 5** Is this patient a good candidate for cryotherapy?
Yes.

Funding provided by the Bill & Melinda Gates Foundation through the Alliance for Cervical Cancer Prevention. The opinions expressed herein are those of Jhpiego.

Flash Card No. 101



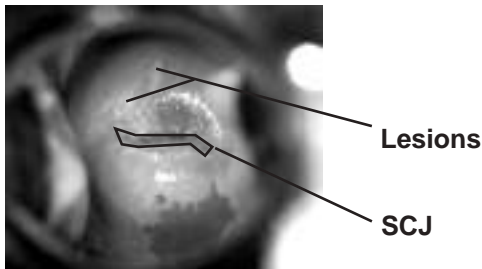
innovating to save lives



an affiliate of Johns Hopkins University



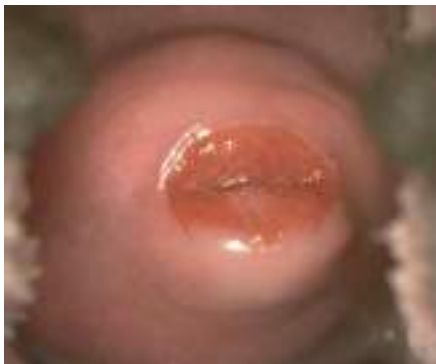Flash Card No. 101 Answers



- Question 1** Is the cervix suspicious for cancer?
No.
- Question 2** If the squamocolumnar junction (SCJ) can be seen on the cervix, point to it.
The SCJ is identified above.
- Question 3** Is the cervix VIA-positive or VIA-negative?
VIA-positive.
- Question 4** Point to the acetowhite lesion(s) on the cervix.
The lesions are identified above.
- Question 5** Is this patient a good candidate for cryotherapy?
Yes.

Funding provided by the Bill & Melinda Gates Foundation through the Alliance for Cervical Cancer Prevention. The opinions expressed herein are those of Jhpiego.

Flash Card No. 102

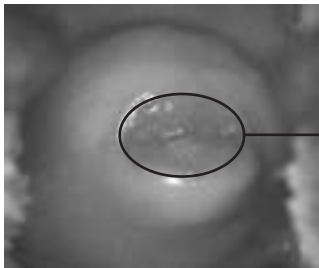


innovating to save lives



an affiliate of Johns Hopkins University

Flash Card No. 102 Answers



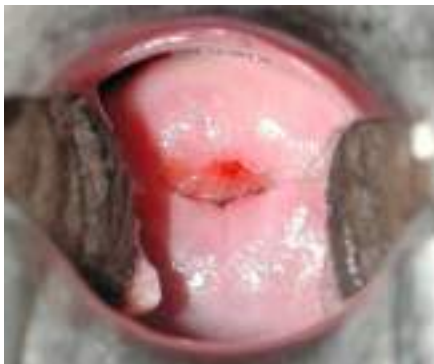SCJ

- Question 1** Is the cervix suspicious for cancer?
No.
- Question 2** If the squamocolumnar junction (SCJ) can be seen on the cervix, point to it.
The SCJ is identified above.
- Question 3** Is the cervix VIA-positive or VIA-negative?
VIA-negative.

[Answer to Q3 is “VIA-negative,” so Q4–5 are skipped.]

Funding provided by the Bill & Melinda Gates Foundation through the Alliance for Cervical Cancer Prevention. The opinions expressed herein are those of Jhpiego.

Flash Card No. 103

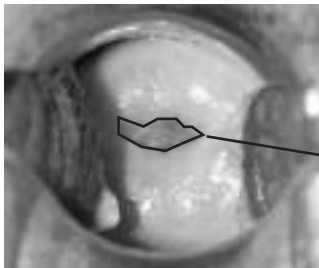


innovating to save lives



an affiliate of Johns Hopkins University

Flash Card No. 103 Answers



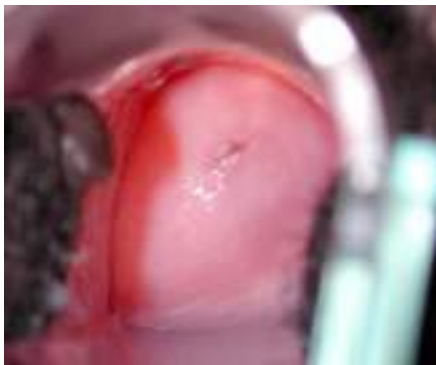SCJ

- Question 1** Is the cervix suspicious for cancer?
No.
- Question 2** If the squamocolumnar junction (SCJ) can be seen on the cervix, point to it.
The SCJ is identified above.
- Question 3** Is the cervix VIA-positive or VIA-negative?
VIA-negative.

[Answer to Q3 is “VIA-negative,” so Q4–5 are skipped.]

Funding provided by the Bill & Melinda Gates Foundation through the Alliance for Cervical Cancer Prevention. The opinions expressed herein are those of Jhpiego.

Flash Card No. 104

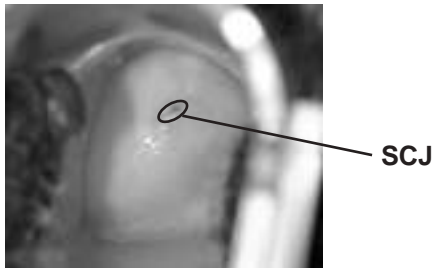


innovating to save lives



an affiliate of Johns Hopkins University

Flash Card No. 104 Answers

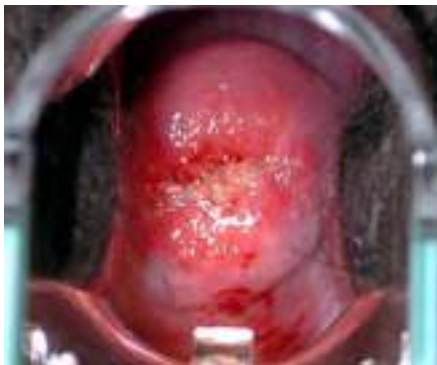

- Question 1** Is the cervix suspicious for cancer?
No.
- Question 2** If the squamocolumnar junction (SCJ) can be seen on the cervix, point to it.
The SCJ is identified above.
- Question 3** Is the cervix VIA-positive or VIA-negative?
VIA-negative.

[Answer to Q3 is “VIA-negative,” so Q4–5 are skipped.]

Funding provided by the Bill & Melinda Gates Foundation through the Alliance for Cervical Cancer Prevention. The opinions expressed herein are those of Jhpiego.

Flash Card No. 105




innovating to save lives



an affiliate of Johns Hopkins University

Flash Card No. 105 Answers

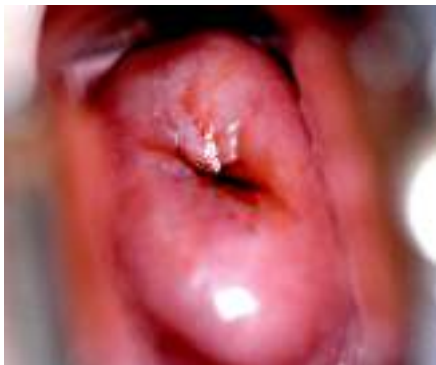

- Question 1** Is the cervix suspicious for cancer?
No.
- Question 2** If the squamocolumnar junction (SCJ) can be seen on the cervix, point to it.
The SCJ is identified above.
- Question 3** Is the cervix VIA-positive or VIA-negative?
VIA-negative.

[Answer to Q3 is “VIA-negative,” so Q4–5 are skipped.]

Funding provided by the Bill & Melinda Gates Foundation through the Alliance for Cervical Cancer Prevention. The opinions expressed herein are those of Jhpiego.

Flash Card No. 106



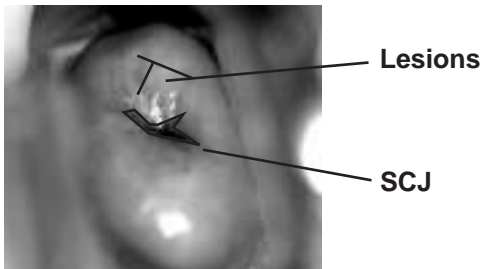
innovating to save lives



an affiliate of Johns Hopkins University



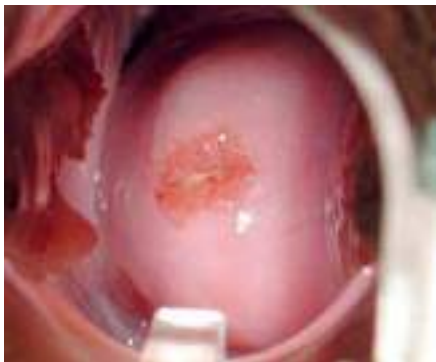Flash Card No. 106 Answers



- Question 1** Is the cervix suspicious for cancer?
No.
- Question 2** If the squamocolumnar junction (SCJ) can be seen on the cervix, point to it.
The SCJ is identified above.
- Question 3** Is the cervix VIA-positive or VIA-negative?
VIA-positive.
- Question 4** Point to the acetowhite lesion(s) on the cervix.
The lesions are identified above.
- Question 5** Is this patient a good candidate for cryotherapy?
Yes.

Funding provided by the Bill & Melinda Gates Foundation through the Alliance for Cervical Cancer Prevention. The opinions expressed herein are those of Jhpiego.

Flash Card No. 107




innovating to save lives



an affiliate of Johns Hopkins University

Flash Card No. 107 Answers

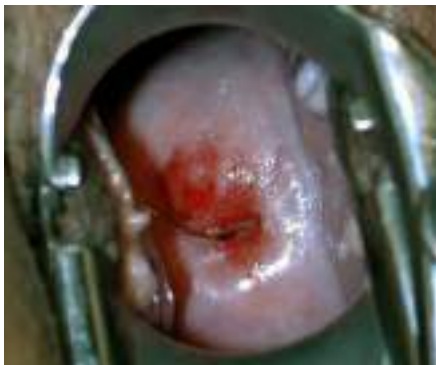

- Question 1** Is the cervix suspicious for cancer?
No.
- Question 2** If the squamocolumnar junction (SCJ) can be seen on the cervix, point to it.
The SCJ is identified above.
- Question 3** Is the cervix VIA-positive or VIA-negative?
VIA-negative.

[Answer to Q3 is “VIA-negative,” so Q4–5 are skipped.]

Funding provided by the Bill & Melinda Gates Foundation through the Alliance for Cervical Cancer Prevention. The opinions expressed herein are those of Jhpiego.

Flash Card No. 108

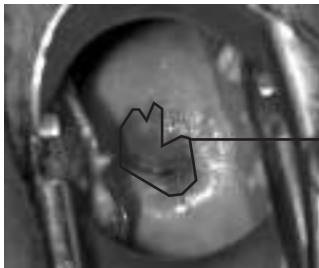


innovating to save lives



an affiliate of Johns Hopkins University

Flash Card No. 108 Answers



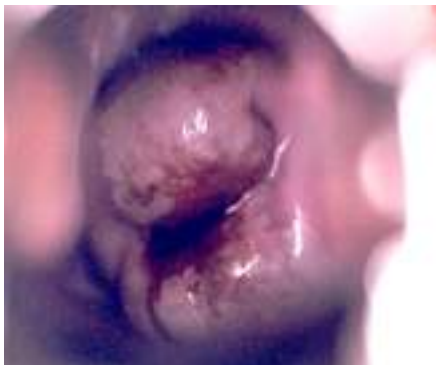SCJ

- Question 1** Is the cervix suspicious for cancer?
No.
- Question 2** If the squamocolumnar junction (SCJ) can be seen on the cervix, point to it.
The SCJ is identified above.
- Question 3** Is the cervix VIA-positive or VIA-negative?
VIA-negative.

[Answer to Q3 is “VIA-negative,” so Q4–5 are skipped.]

Funding provided by the Bill & Melinda Gates Foundation through the Alliance for Cervical Cancer Prevention. The opinions expressed herein are those of Jhpiego.

Flash Card No. 109



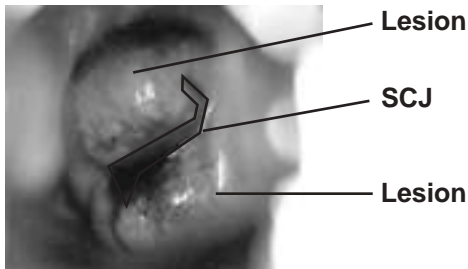
innovating to save lives



an affiliate of Johns Hopkins University



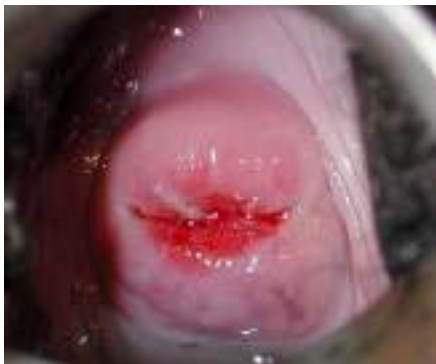Flash Card No. 109 Answers



- Question 1** Is the cervix suspicious for cancer?
No.
- Question 2** If the squamocolumnar junction (SCJ) can be seen on the cervix, point to it.
The SCJ is identified above.
- Question 3** Is the cervix VIA-positive or VIA-negative?
VIA-positive.
- Question 4** Point to the acetowhite lesion(s) on the cervix.
The lesions are identified above.
- Question 5** Is this patient a good candidate for cryotherapy?
No. The lesions extend too far on the cervix (will not be covered by cryoprobe).

Funding provided by the Bill & Melinda Gates Foundation through the Alliance for Cervical Cancer Prevention. The opinions expressed herein are those of Jhpiego.

Flash Card No. 110

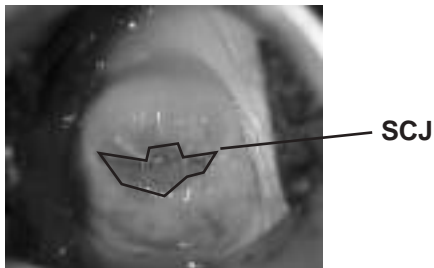


innovating to save lives



an affiliate of Johns Hopkins University

Flash Card No. 110 Answers



Question 1 Is the cervix suspicious for cancer?
No.

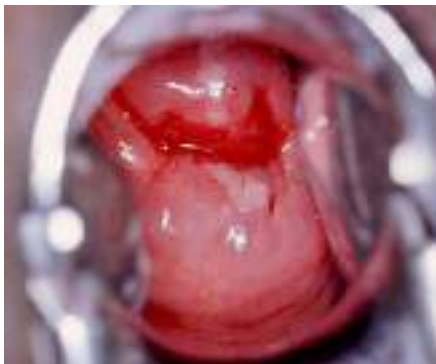Question 2 If the squamocolumnar junction (SCJ) can be seen on the cervix, point to it.
The SCJ is identified above.

Question 3 Is the cervix VIA-positive or VIA-negative?
VIA-negative.

[Answer to Q3 is “VIA-negative,” so Q4–5 are skipped.]

Funding provided by the Bill & Melinda Gates Foundation through the Alliance for Cervical Cancer Prevention. The opinions expressed herein are those of Jhpiego.

Flash Card No. 111



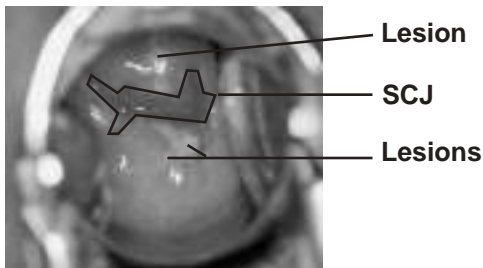
innovating to save lives



an affiliate of Johns Hopkins University



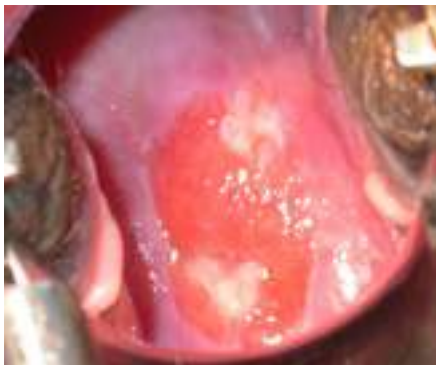Flash Card No. 111 Answers



- Question 1** Is the cervix suspicious for cancer?
No.
- Question 2** If the squamocolumnar junction (SCJ) can be seen on the cervix, point to it.
The SCJ is identified above.
- Question 3** Is the cervix VIA-positive or VIA-negative?
VIA-positive.
- Question 4** Point to the acetowhite lesion(s) on the cervix.
The lesions are identified above.
- Question 5** Is this patient a good candidate for cryotherapy?
Yes.

Funding provided by the Bill & Melinda Gates Foundation through the Alliance for Cervical Cancer Prevention. The opinions expressed herein are those of Jhpiego.

Flash Card No. 112



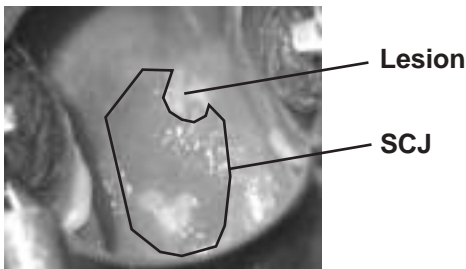
innovating to save lives



an affiliate of Johns Hopkins University



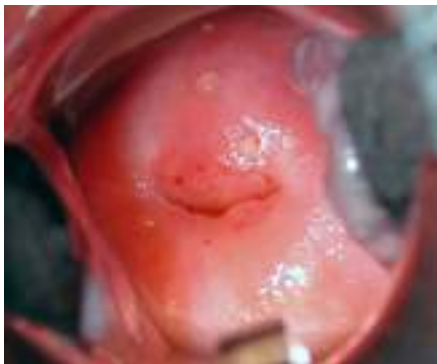Flash Card No. 112 Answers



- Question 1** Is the cervix suspicious for cancer?
No.
- Question 2** If the squamocolumnar junction (SCJ) can be seen on the cervix, point to it.
The SCJ is identified above.
- Question 3** Is the cervix VIA-positive or VIA-negative?
VIA-positive.
- Question 4** Point to the acetowhite lesion(s) on the cervix.
The lesion is identified above.
- Question 5** Is this patient a good candidate for cryotherapy?
Yes.

Funding provided by the Bill & Melinda Gates Foundation through the Alliance for Cervical Cancer Prevention. The opinions expressed herein are those of Jhpiego.

Flash Card No. 113

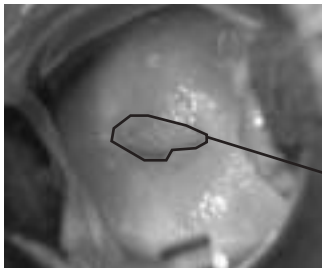

innovating to save lives



an affiliate of Johns Hopkins University

Flash Card No. 113 Answers



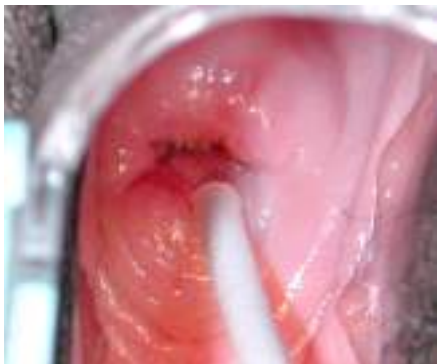SCJ

- Question 1** Is the cervix suspicious for cancer?
No.
- Question 2** If the squamocolumnar junction (SCJ) can be seen on the cervix, point to it.
The SCJ is identified above.
- Question 3** Is the cervix VIA-positive or VIA-negative?
VIA-negative.

[Answer to Q3 is “VIA-negative,” so Q4–5 are skipped.]

Funding provided by the Bill & Melinda Gates Foundation through the Alliance for Cervical Cancer Prevention. The opinions expressed herein are those of Jhpiego.

Flash Card No. 114

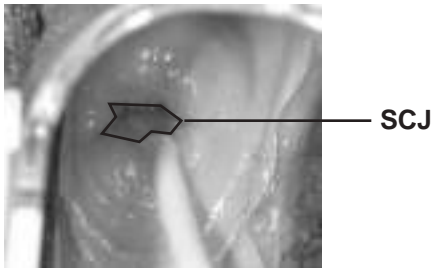


innovating to save lives



an affiliate of Johns Hopkins University

Flash Card No. 114 Answers

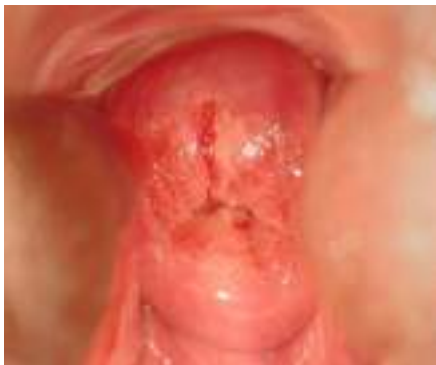

- Question 1** Is the cervix suspicious for cancer?
No.
- Question 2** If the squamocolumnar junction (SCJ) can be seen on the cervix, point to it.
The SCJ is identified above.
- Question 3** Is the cervix VIA-positive or VIA-negative?
VIA-negative.

[Answer to Q3 is “VIA-negative,” so Q4–5 are skipped.]

Funding provided by the Bill & Melinda Gates Foundation through the Alliance for Cervical Cancer Prevention. The opinions expressed herein are those of Jhpiego.

Flash Card No. 115



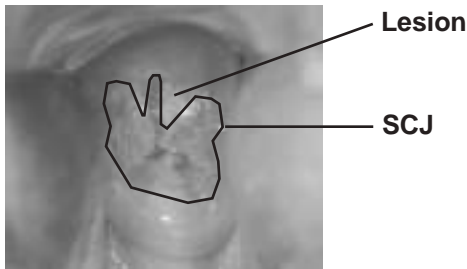
innovating to save lives



an affiliate of Johns Hopkins University



Flash Card No. 115 Answers






- Question 1** Is the cervix suspicious for cancer?
No.
- Question 2** If the squamocolumnar junction (SCJ) can be seen on the cervix, point to it.
The SCJ is identified above.
- Question 3** Is the cervix VIA-positive or VIA-negative?
VIA-positive.
- Question 4** Point to the acetowhite lesion(s) on the cervix.
The lesion is identified above.
- Question 5** Is this patient a good candidate for cryotherapy?
Yes.

Funding provided by the Bill & Melinda Gates Foundation through the Alliance for Cervical Cancer Prevention. The opinions expressed herein are those of Jhpiego.

Index Card

As described in **About This Card Set**, the following is a list of all the flash cards in this set, listed by diagnosis.

 NEGATIVE	 POSITIVE	 Suspicious for CANCER
3 44 82	1 42 84	5
4 47 83	2 43 86	7
6 48 85	8 45 89	25
9 50 87	10 46 90	55
12 52 93	11 49 91	65
14 53 94	13 51 92	88
15 54 96	17 59 95	
16 56 98	18 61 97	
19 57 102	20 63 99	
22 58 103	21 64 100	
26 60 104	23 68 101	
27 62 105	24 69 106	
30 66 107	28 70 109	
31 67 108	29 72 111	
33 71 110	32 73 112	
34 74 113	35 77 115	
37 75 114	36 78	
40 76	38 80	
41 79	39 81	

innovating to save lives



an affiliate of Johns Hopkins University

Funding provided by the Bill & Melinda Gates Foundation through the Alliance for Cervical Cancer Prevention. The opinions expressed herein are those of Jhpiego.